

# Management of the Newborn with ARM

**Luis de la Torre, MD**

The 65<sup>th</sup> Workshop for the Surgical Treatment  
of Colorectal Problems in Children



Children's Hospital Colorado  
*Here, it's different.™*

# Neonatal Management

What is the first and most important objective you need to do in a newborn with an anorectal malformation?

1. Evaluate the sacral ratio to notify the parents about the prognosis of the fecal control
2. Discard life-threatening malformations
3. Decide if you do a colostomy
4. Decide if you do an anoplasty
5. Identify if the patient has a clinically evident fistula



# Neonatal Management

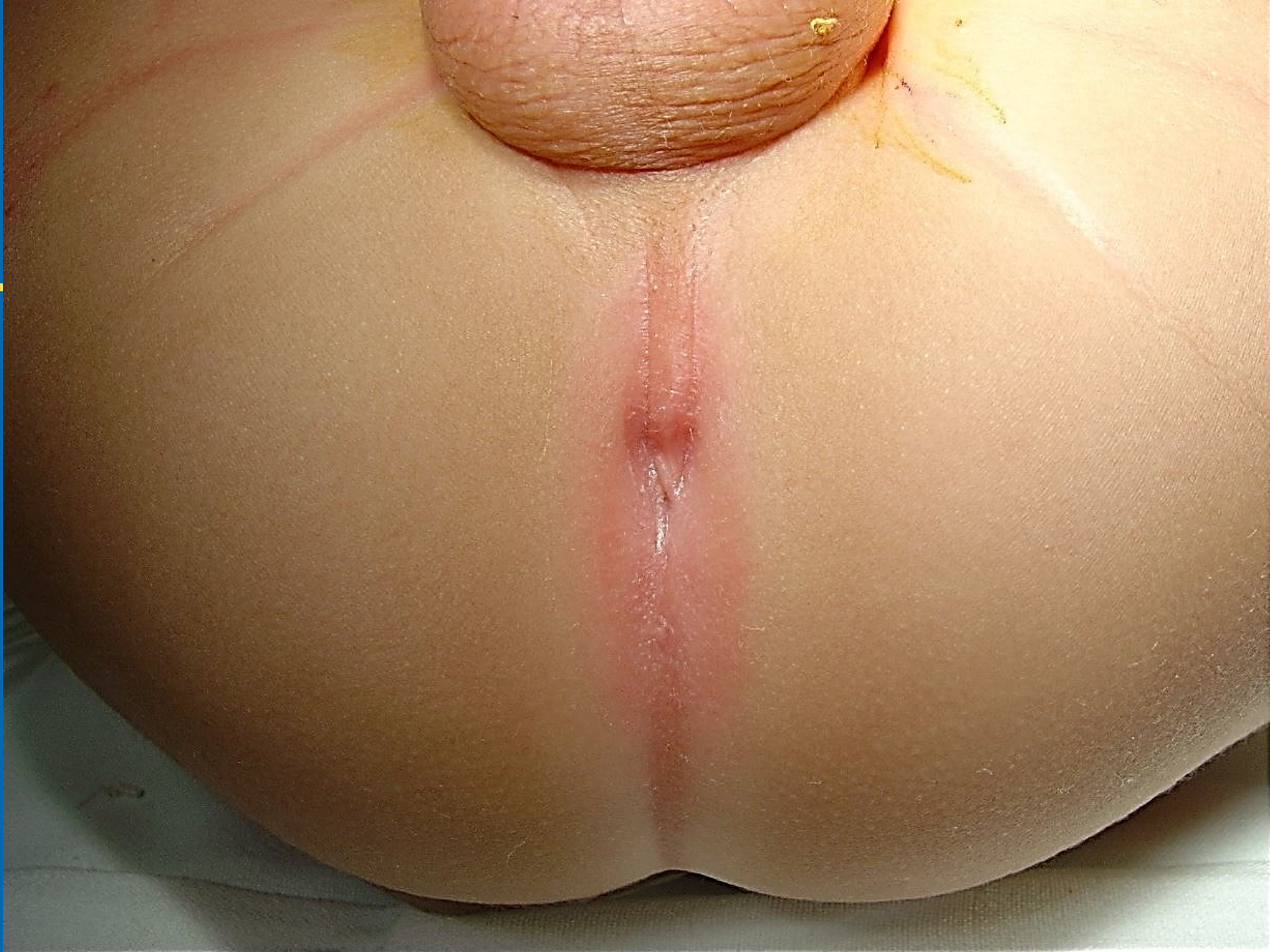---

- Life-threatening associated anomalies ?
- Colostomy or anoplasty?

# Neonatal Management

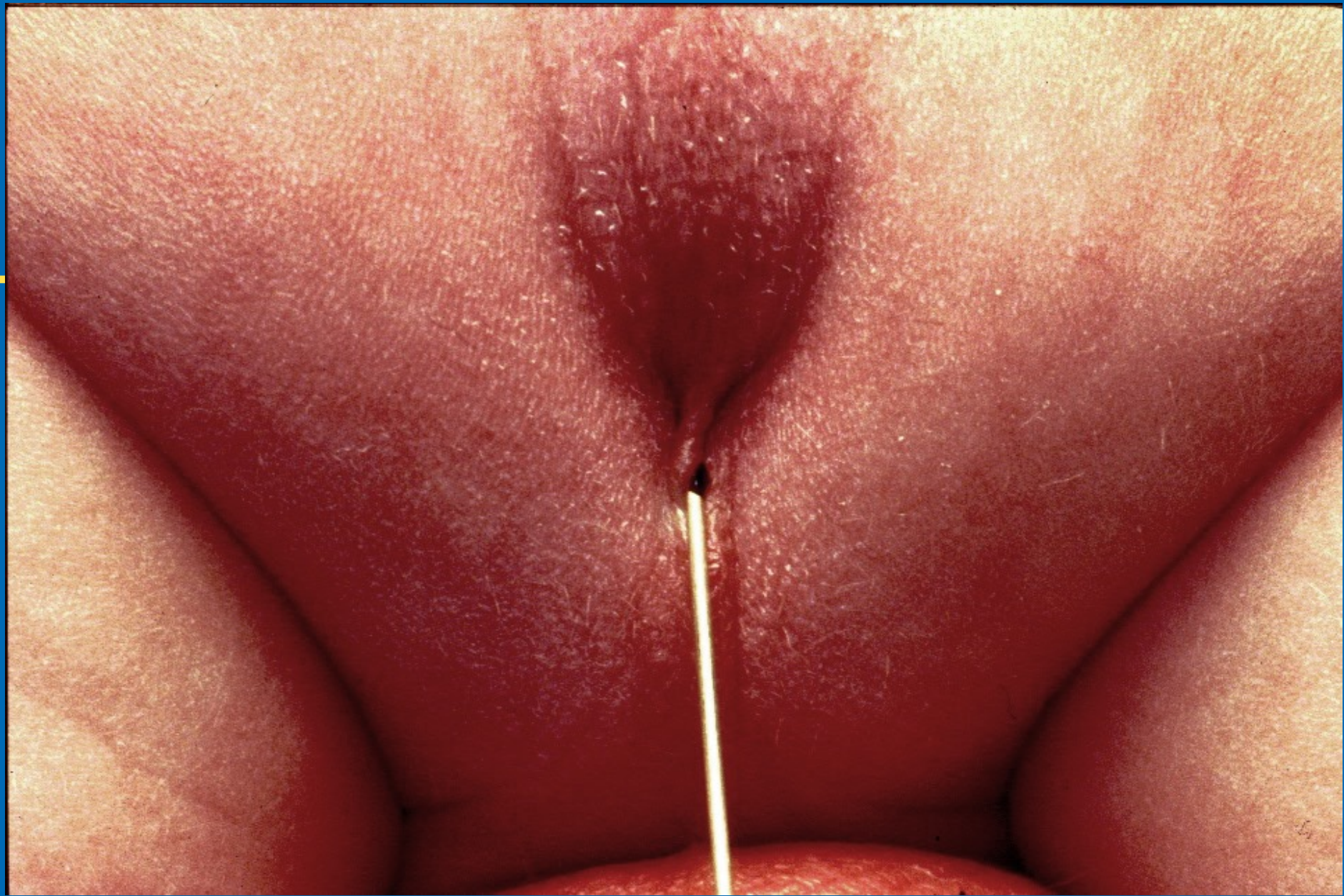---

- Does the baby have a clinically evident fistula?



Children's Hospital Colorado  
*Here, it's different.™*

INTERNATIONAL CENTER FOR  
**COLORECTAL AND  
UROGENITAL CARE**



**Children's Hospital Colorado**  
*Here, it's different.™*

INTERNATIONAL CENTER FOR  
**COLORECTAL AND  
UROGENITAL CARE**

# Associated Defects

What is the most frequent congenital malformation associated in patients with imperforate anus?

1. Atrial septal defect
2. Tethered cord
3. Hemi-sacrum
4. Hydronephrosis
5. Esophageal atresia



# Associated Defects

- Abdominal/kidney ultrasound
  - Hydronephrosis? (50%)
  - Hydrocolpos? (30%)
- Echocardiogram (30%)
- GI Defects 8% EA, 3% duodenal atresia
- Lumbar spine
- Sacrum hemi-sacrum and sacral ratio
- Spinal ultrasound
  - Tethered cord? (25%)





# How many hours do you wait to perform a colostomy or an anoplasty?

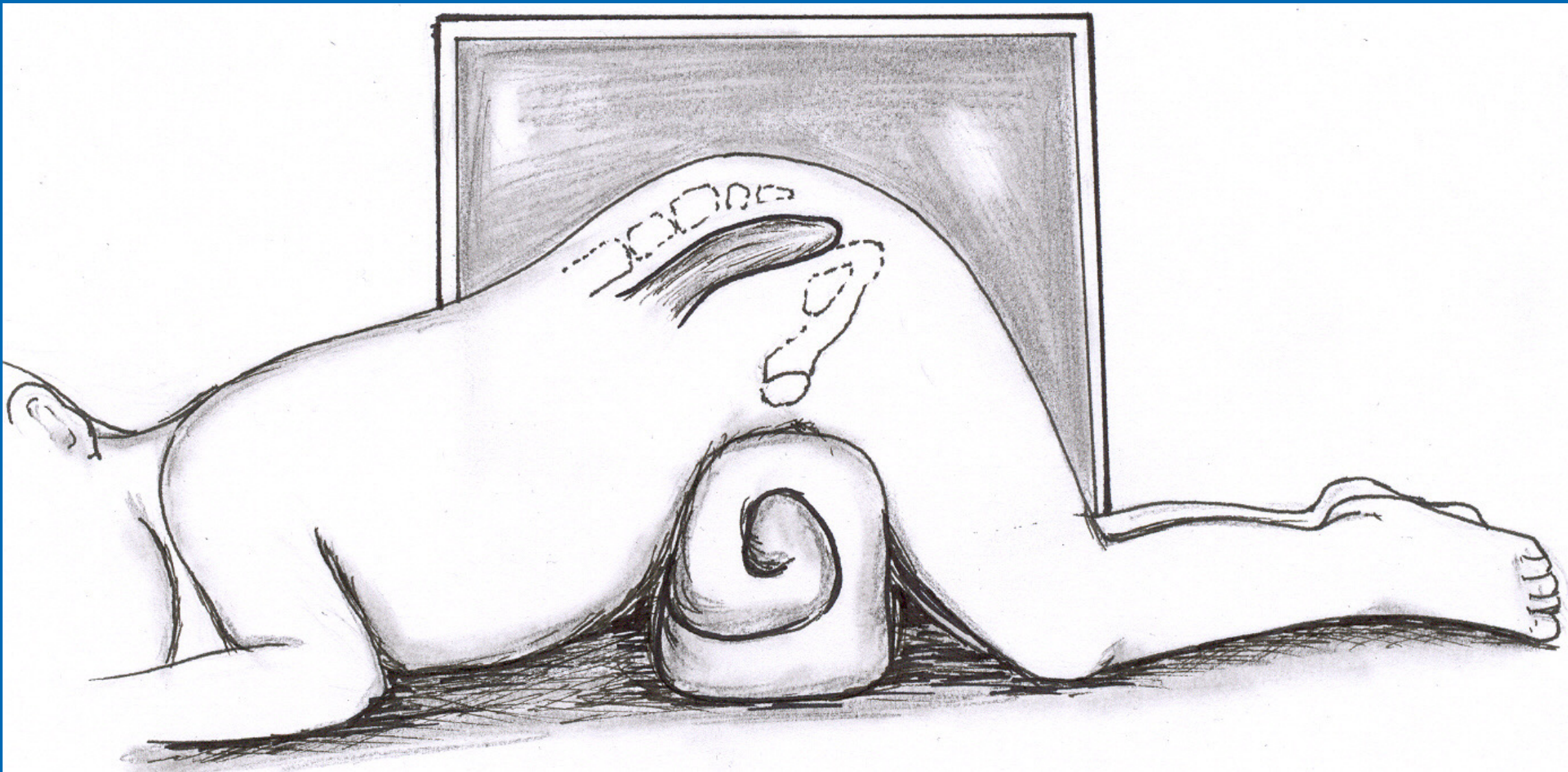
1. 48 hours
2. 12 hours
3. 24 hours
4. 36 hours
5. 72 hours



# Colostomy vs. Anoplasty

- Wait 24 hours
- Meticulous Inspection of perineum
- Urinalysis, meconuria
- Crosstable lateral film

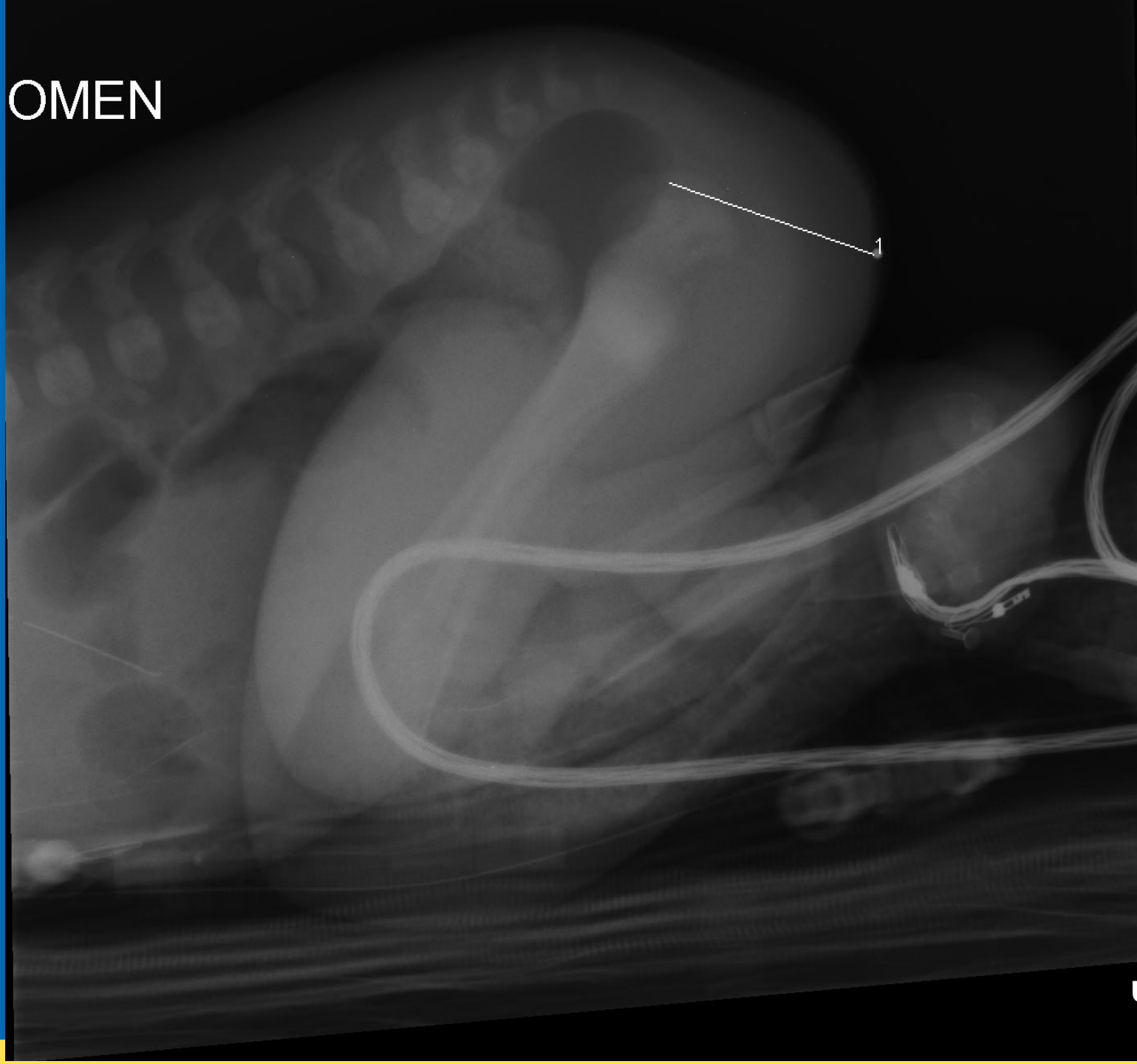




Children's Hospital Colorado  
*Here, it's different.™*

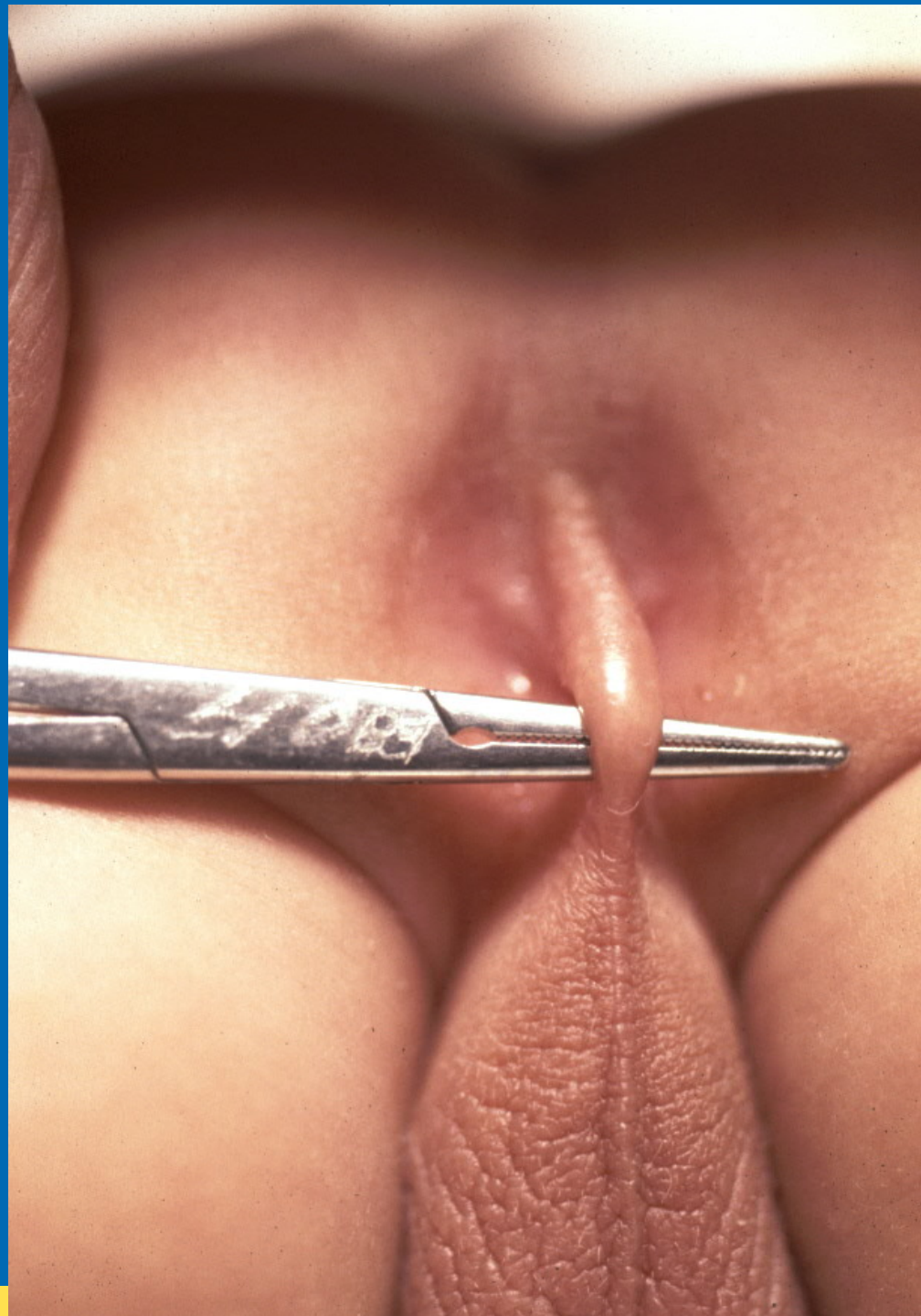INTERNATIONAL CENTER FOR  
**COLORECTAL AND  
UROGENITAL CARE**

# OMEN



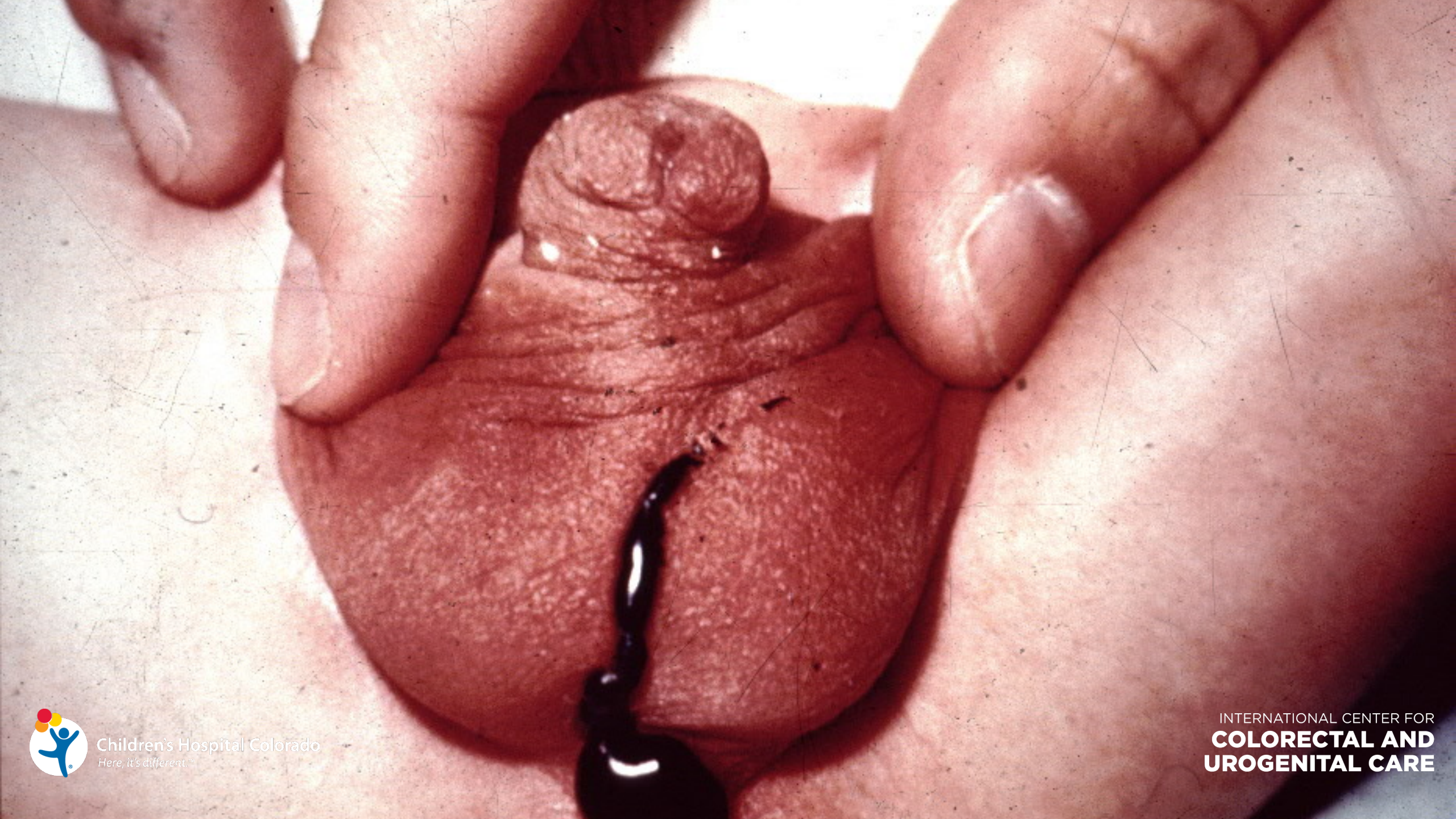Children's Hospital Colorado  
*Here, it's different.™*

INTERNATIONAL CENTER FOR  
**COLORECTAL AND  
UROGENITAL CARE**



**Children's Hospital Colorado**  
*Here, it's different.™*

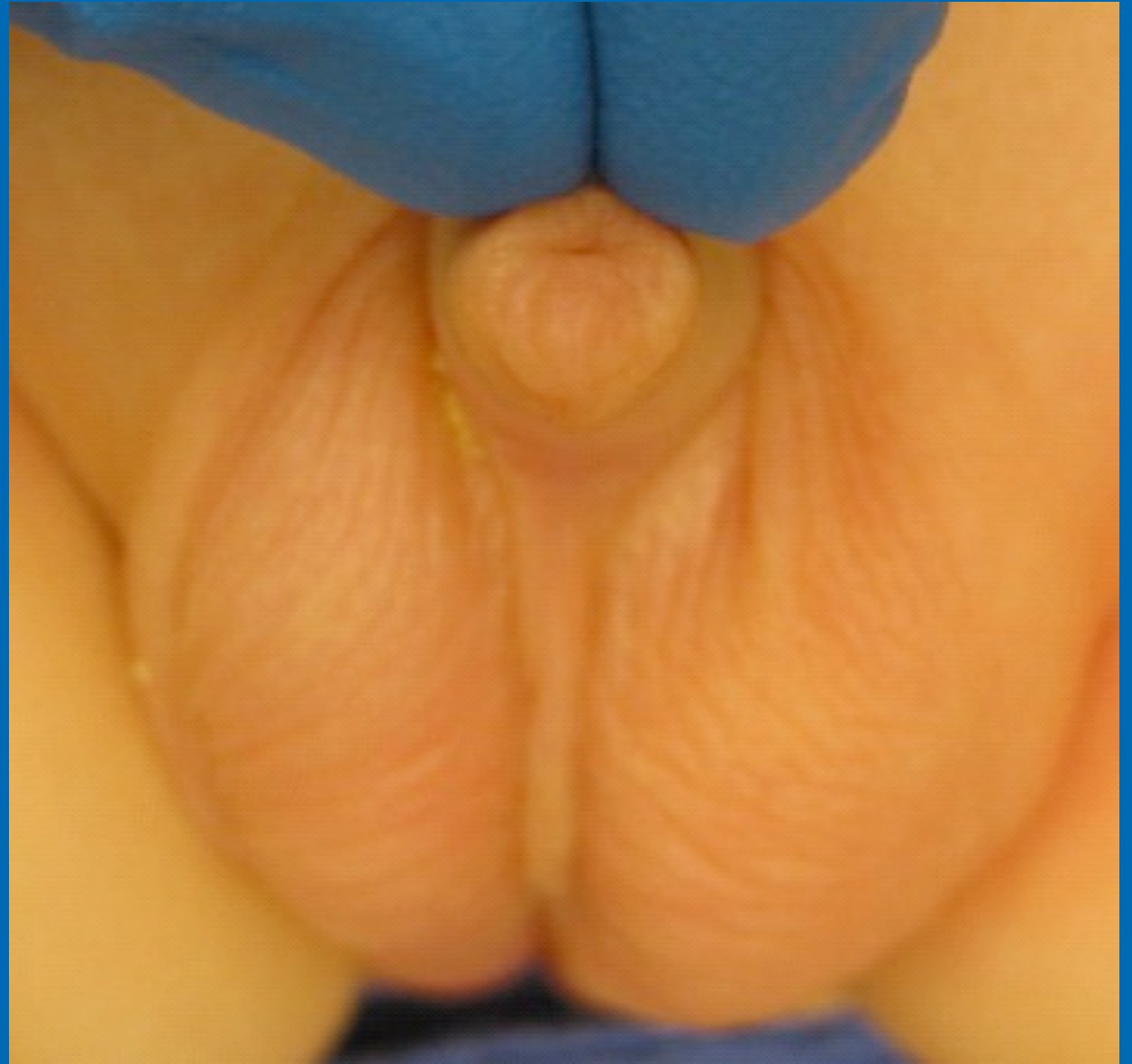INTERNATIONAL CENTER FOR  
**COLORECTAL AND  
UROGENITAL CARE**

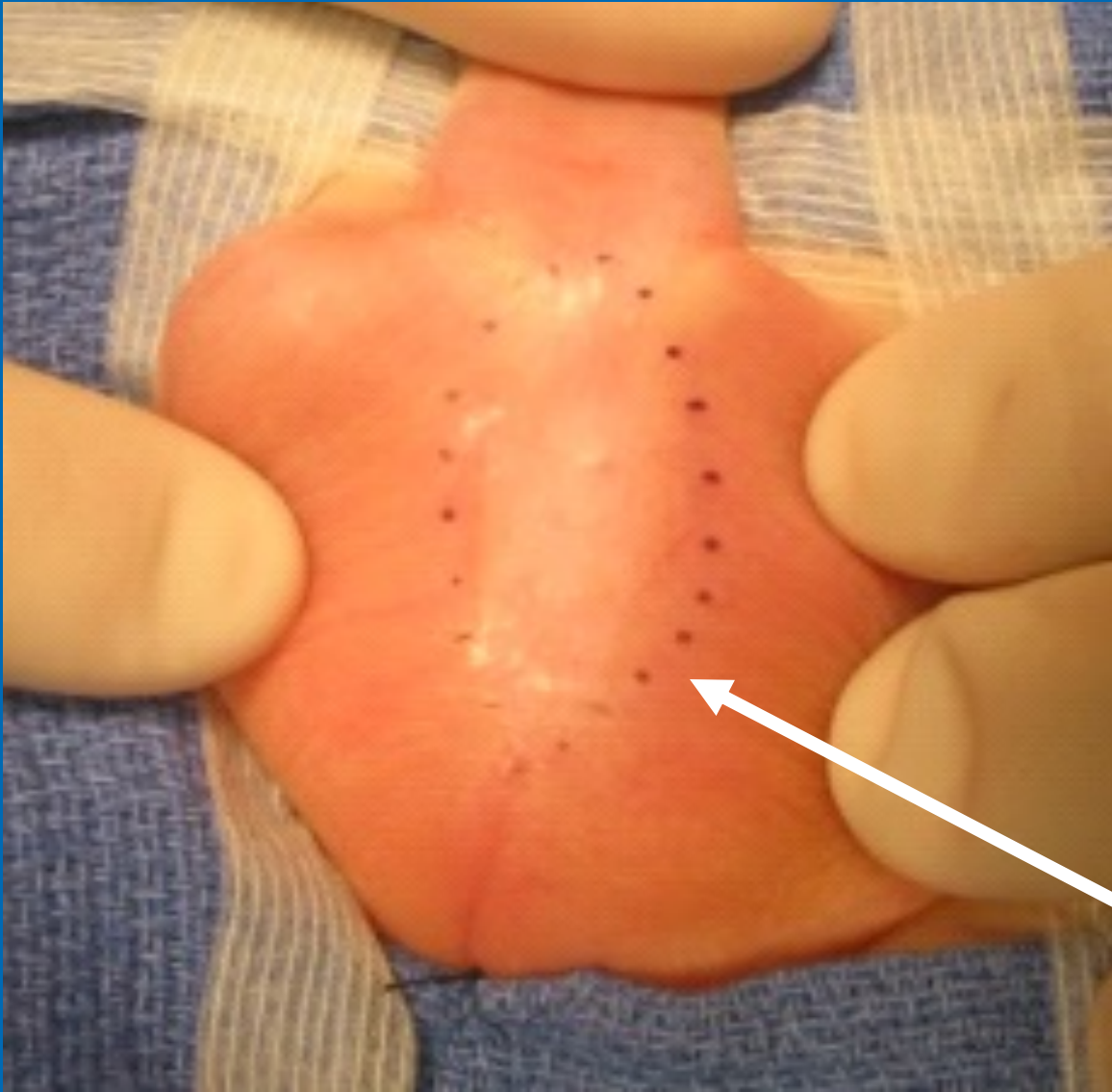


Children's Hospital Colorado  
*Here, it's different.™*

INTERNATIONAL CENTER FOR  
**COLORECTAL AND  
UROGENITAL CARE**

# Bifid Scrotum

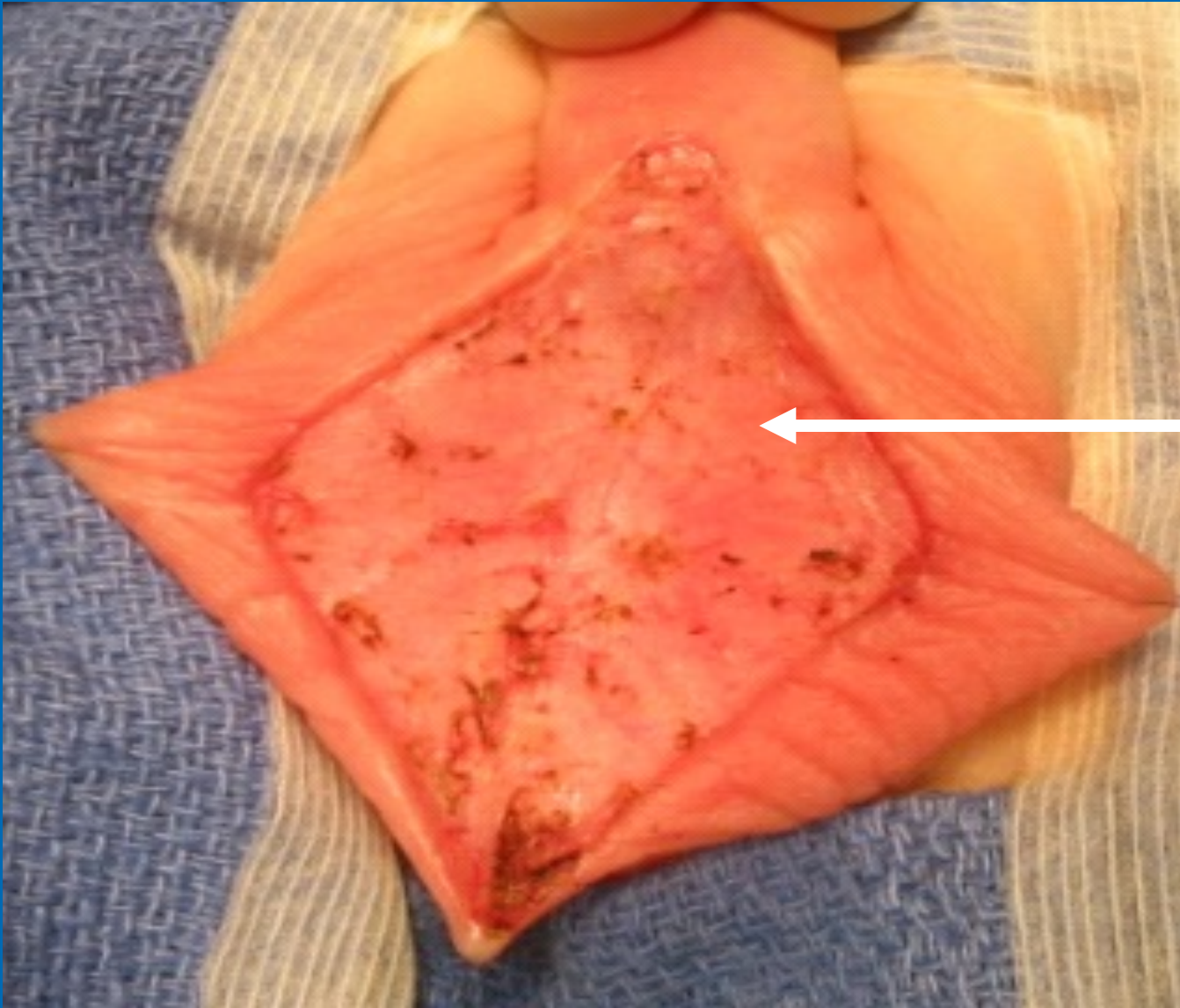




**Incision Line**







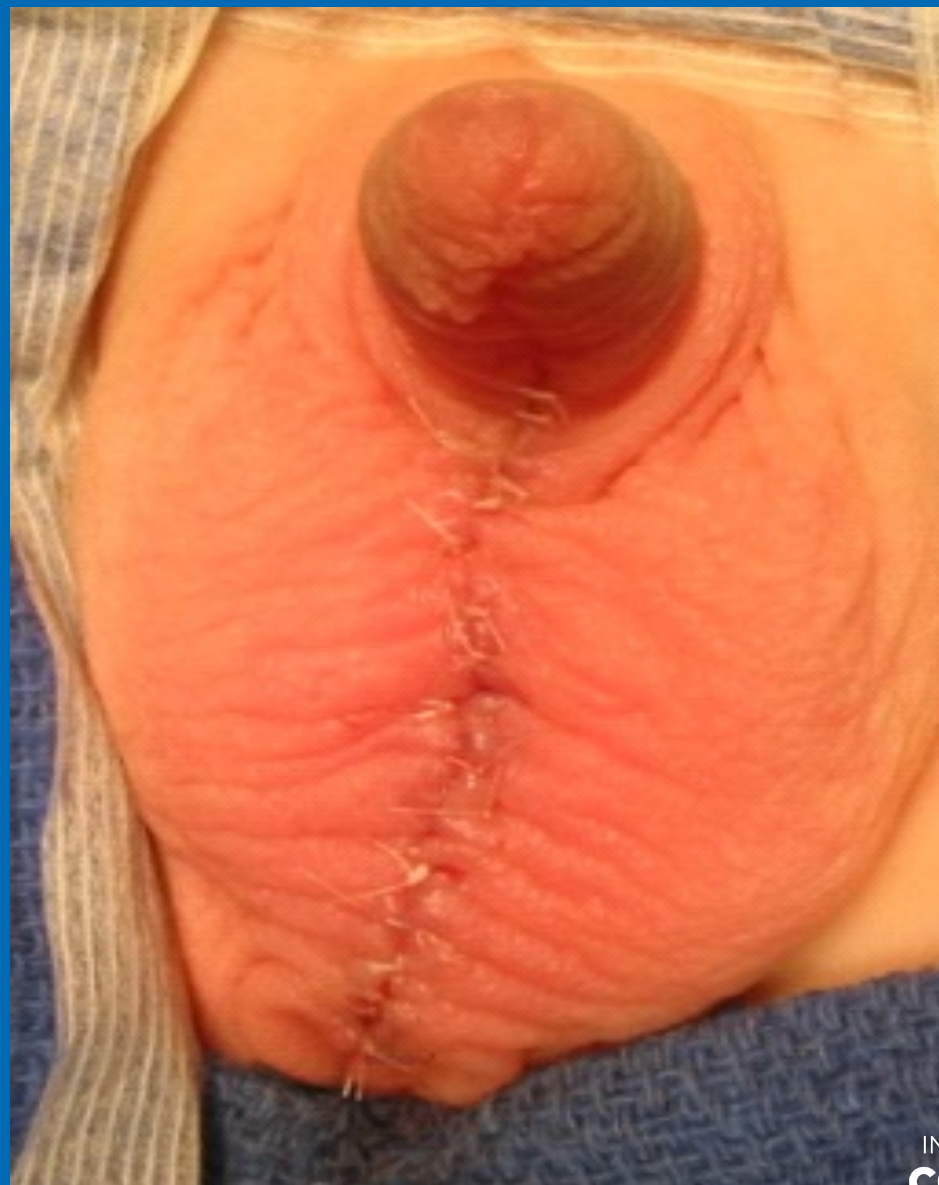**Abnormal  
resected  
skin**



**Children's Hospital Colorado**  
*Here, it's different.™*

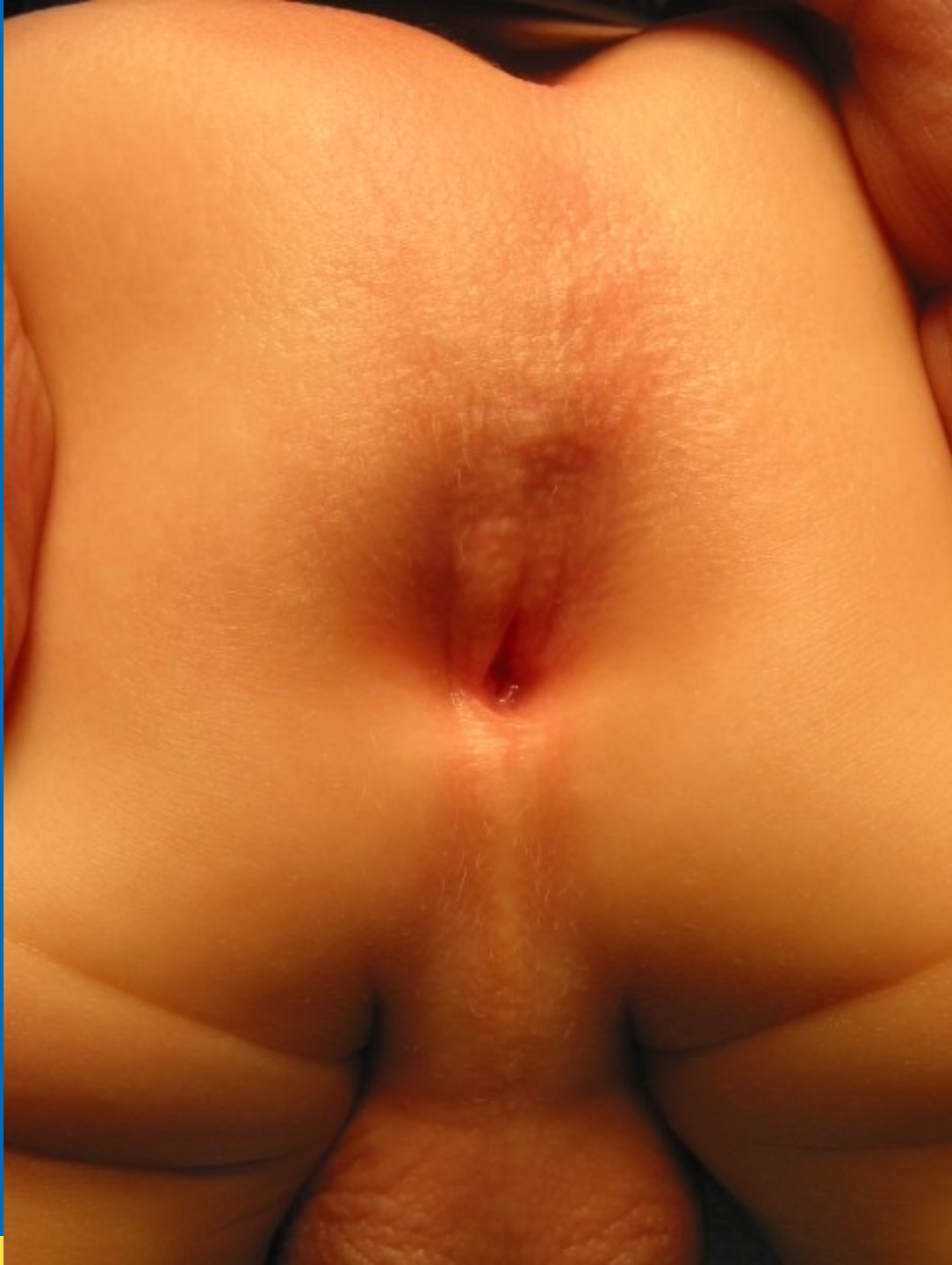INTERNATIONAL CENTER FOR  
**COLORECTAL AND  
UROGENITAL CARE**

# Final Aspect



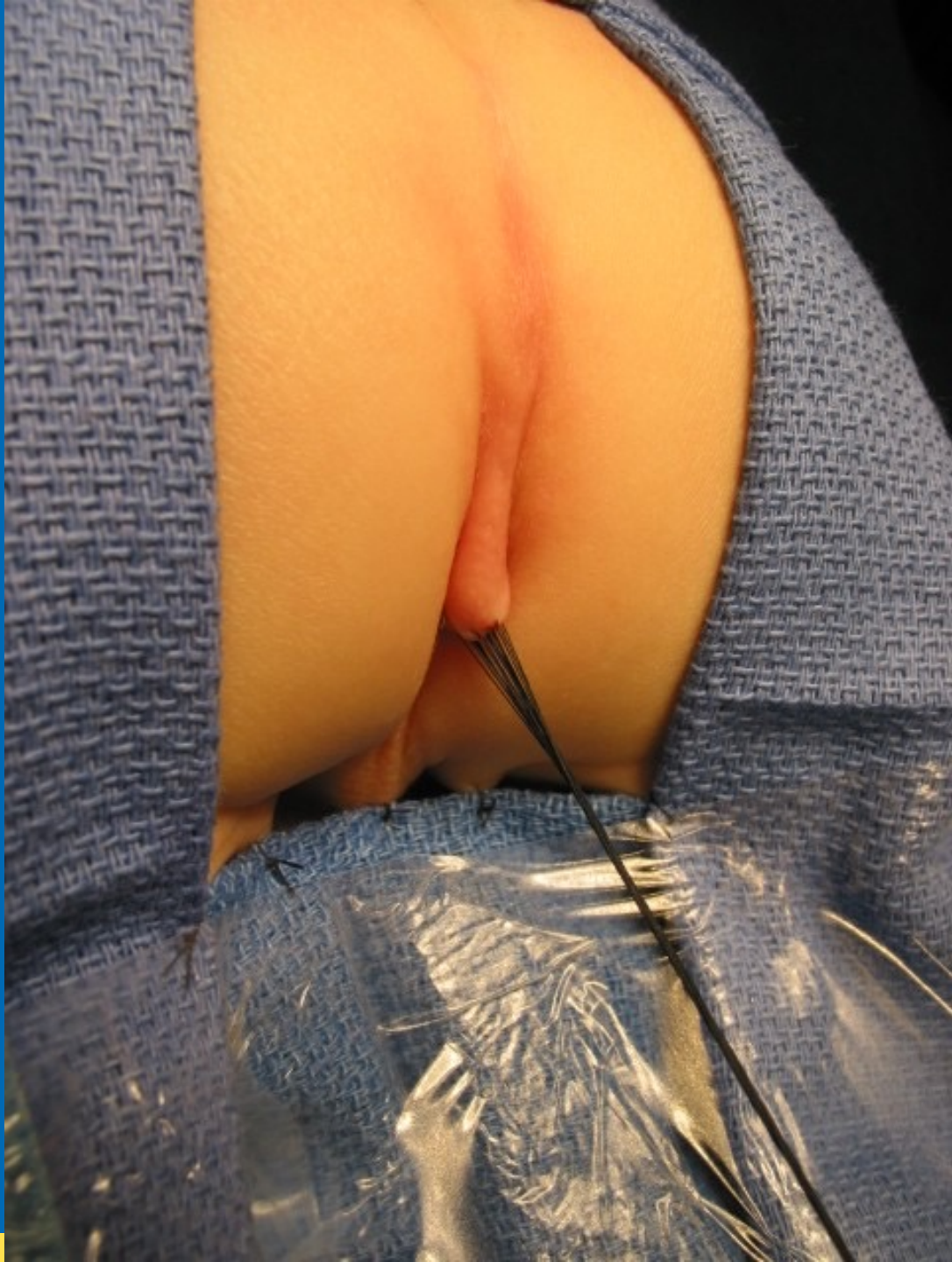Children's Hospital Colorado  
*Here, it's different.™*

INTERNATIONAL CENTER FOR  
**COLORECTAL AND  
UROGENITAL CARE**



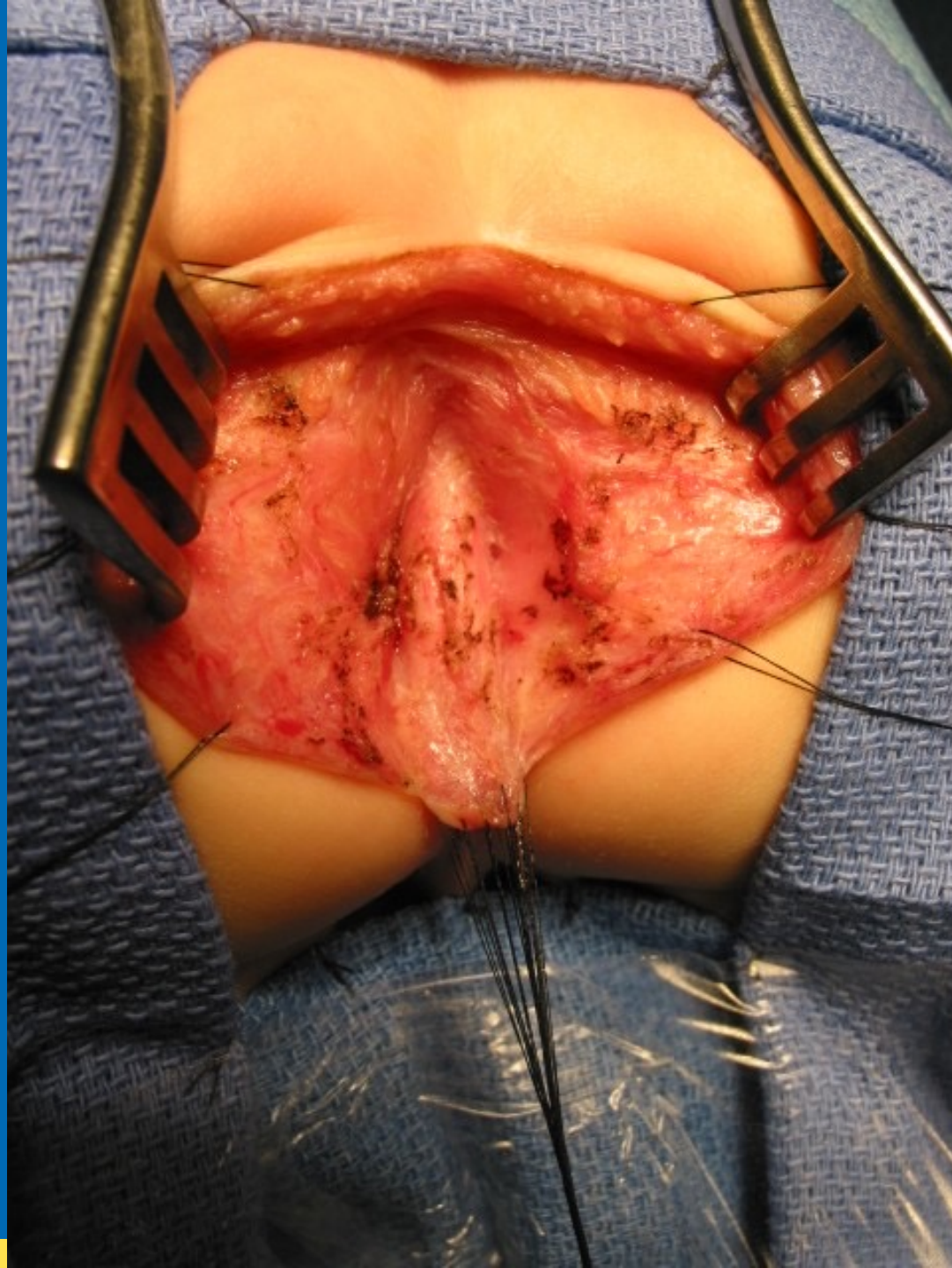
**Children's Hospital Colorado**  
*Here, it's different.™*

INTERNATIONAL CENTER FOR  
**COLORECTAL AND  
UROGENITAL CARE**



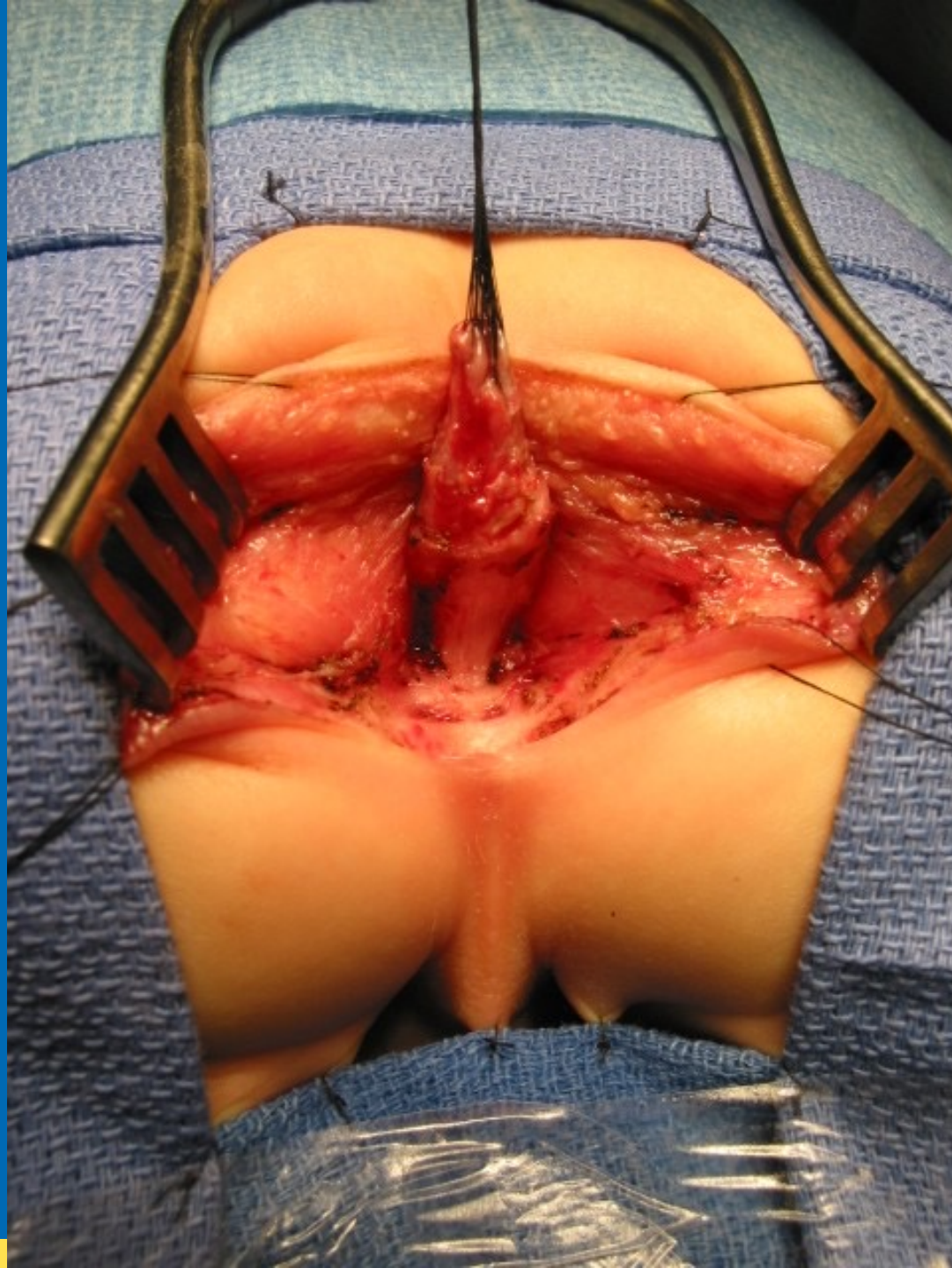
**Children's Hospital Colorado**  
*Here, it's different.™*

INTERNATIONAL CENTER FOR  
**COLORECTAL AND  
UROGENITAL CARE**



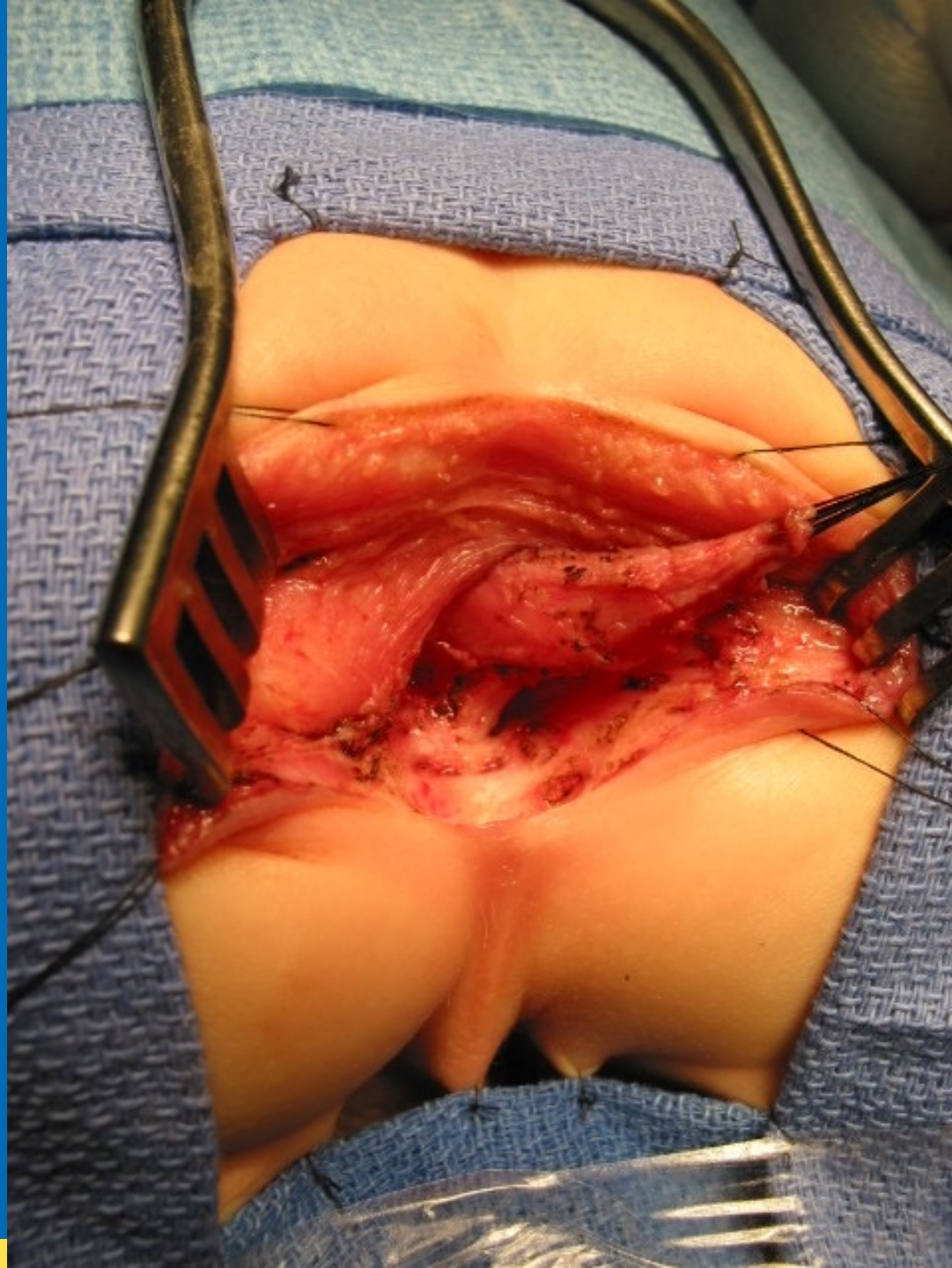
**Children's Hospital Colorado**  
*Here, it's different.™*

INTERNATIONAL CENTER FOR  
**COLORECTAL AND  
UROGENITAL CARE**



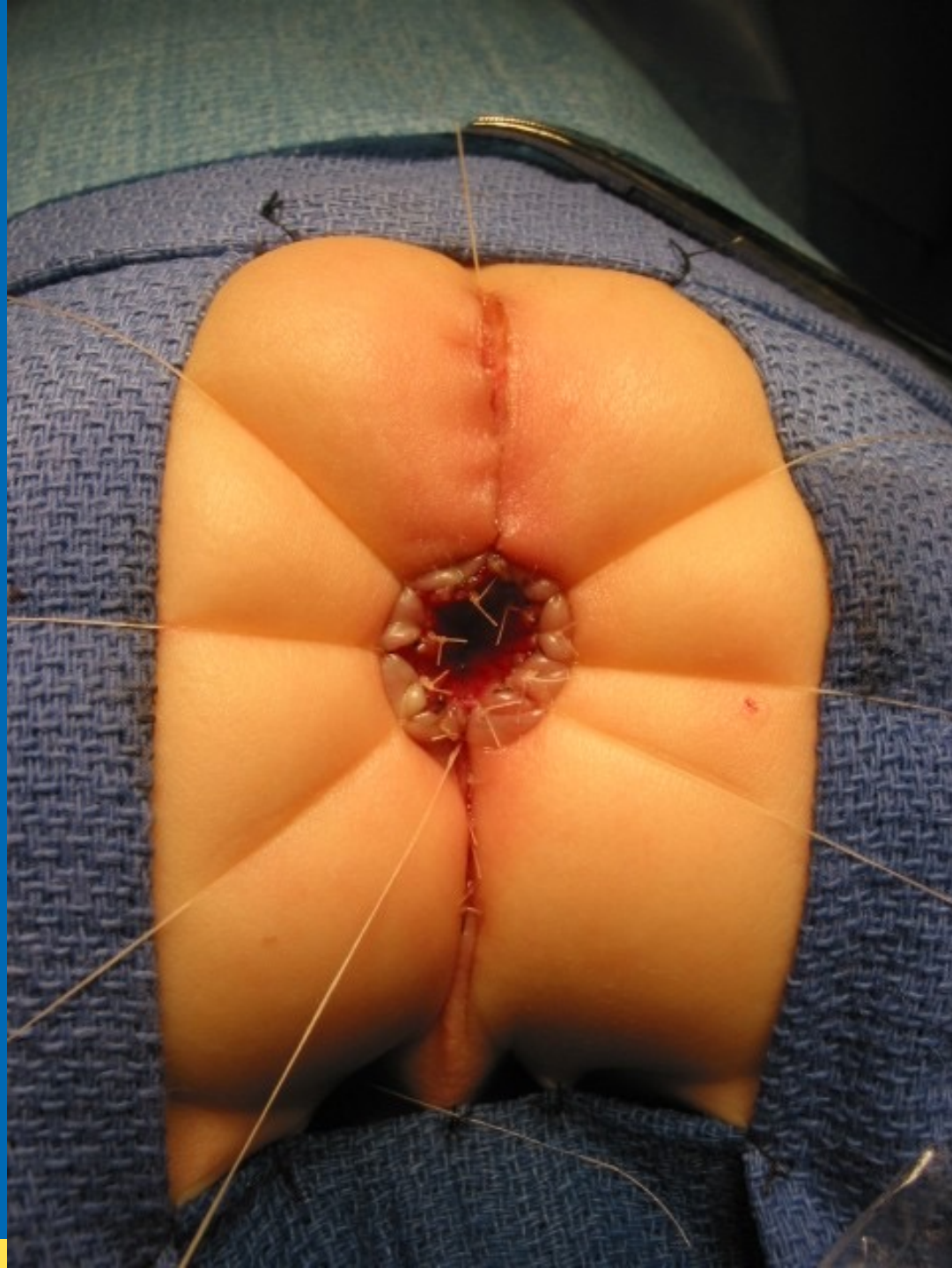
**Children's Hospital Colorado**  
*Here, it's different.™*

INTERNATIONAL CENTER FOR  
**COLORECTAL AND  
UROGENITAL CARE**



**Children's Hospital Colorado**  
*Here, it's different.™*

INTERNATIONAL CENTER FOR  
**COLORECTAL AND  
UROGENITAL CARE**



**Children's Hospital Colorado**  
*Here, it's different.™*

INTERNATIONAL CENTER FOR  
**COLORECTAL AND  
UROGENITAL CARE**

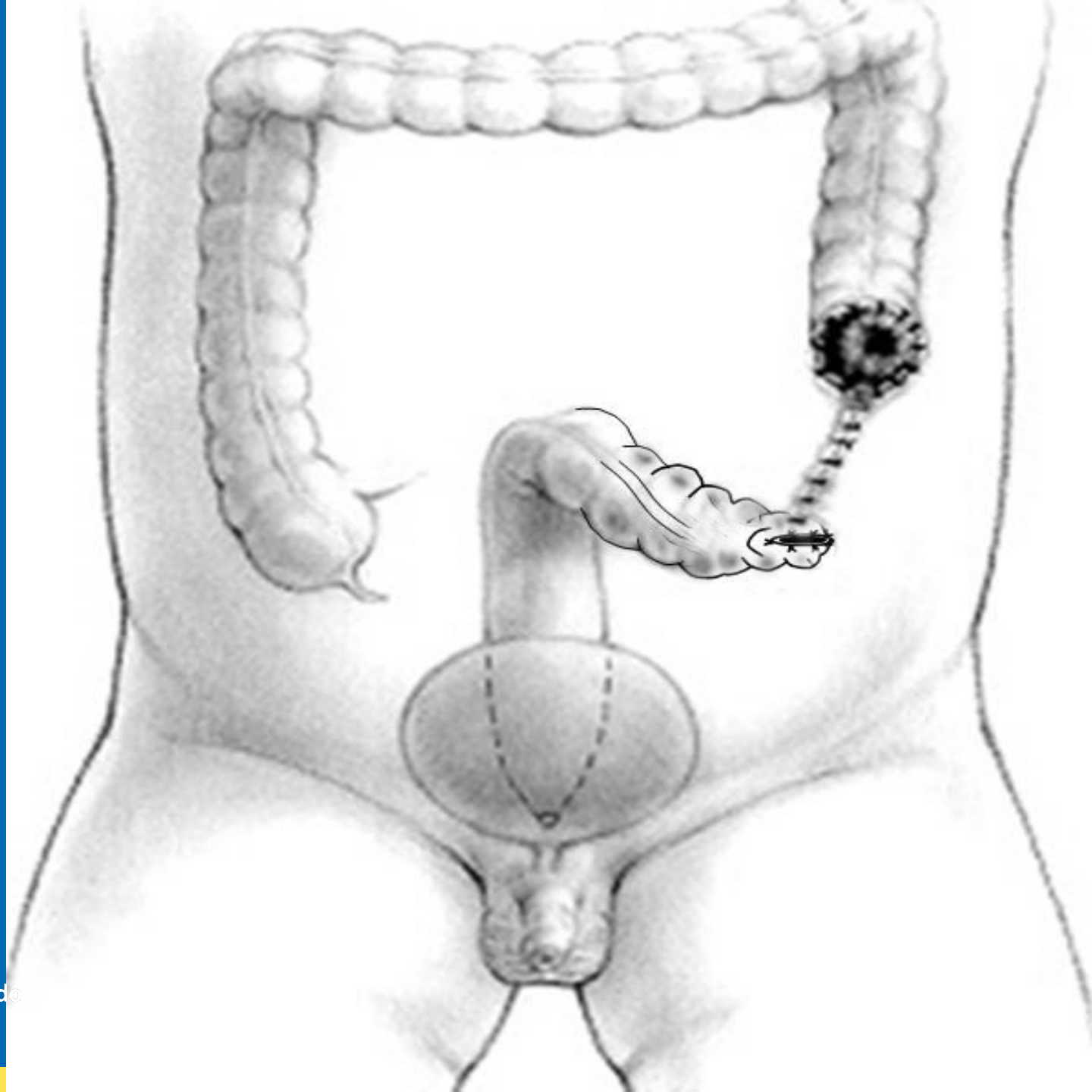


# Neonatal Management

Which is the type of colostomy recommended in patients with an anorectal malformation?

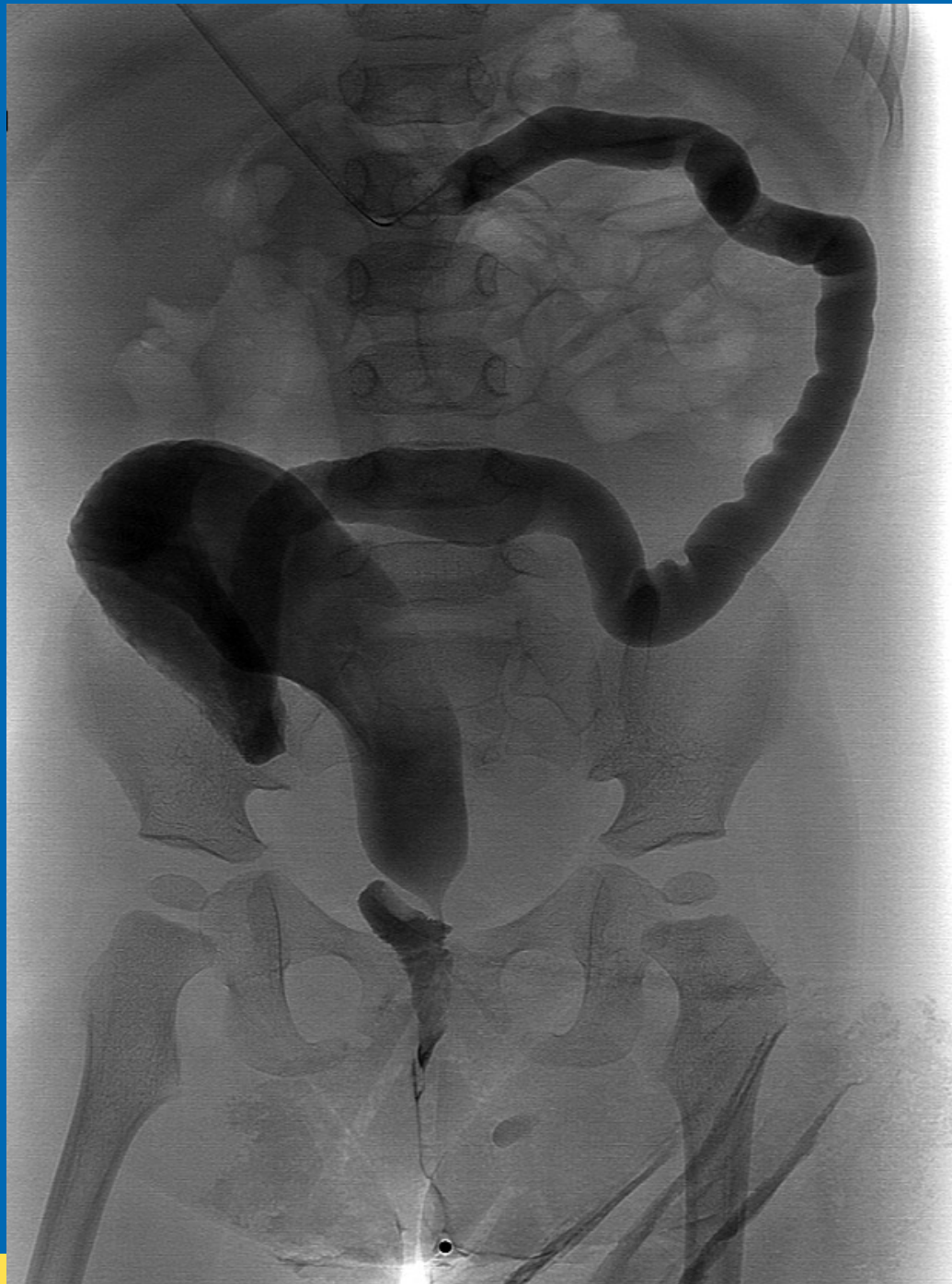1. Loop colostomy
2. End colostomy and Hartmann's pouch
3. Sigmoidostomy with mucous fistula
4. Proximal descending colostomy with mucous fistula
5. Distal descending colostomy with mucous fistula





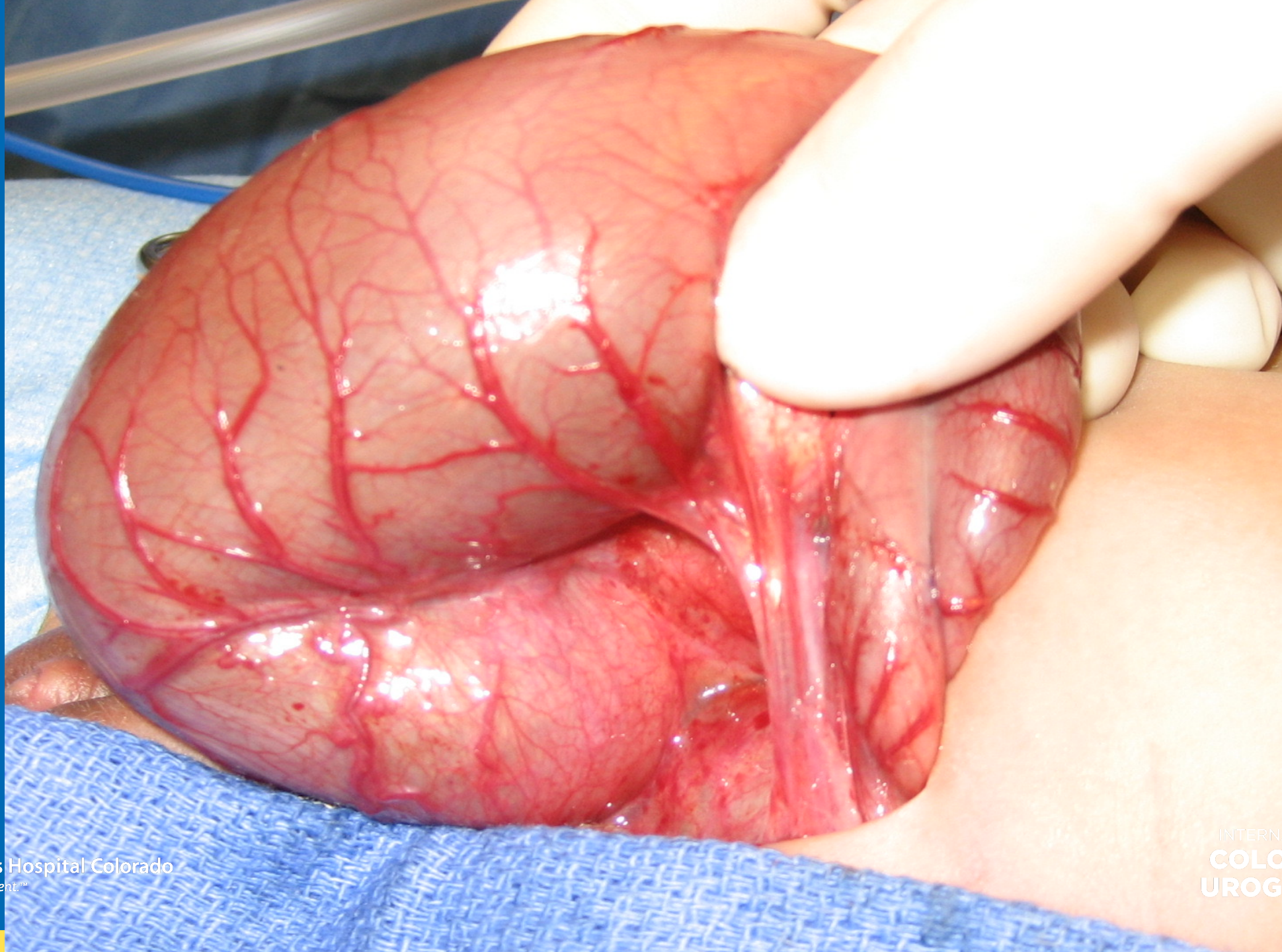
Children's Hospital Colorado  
*Here, it's different.™*

INTERNATIONAL CENTER FOR  
**COLORECTAL AND  
UROGENITAL CARE**



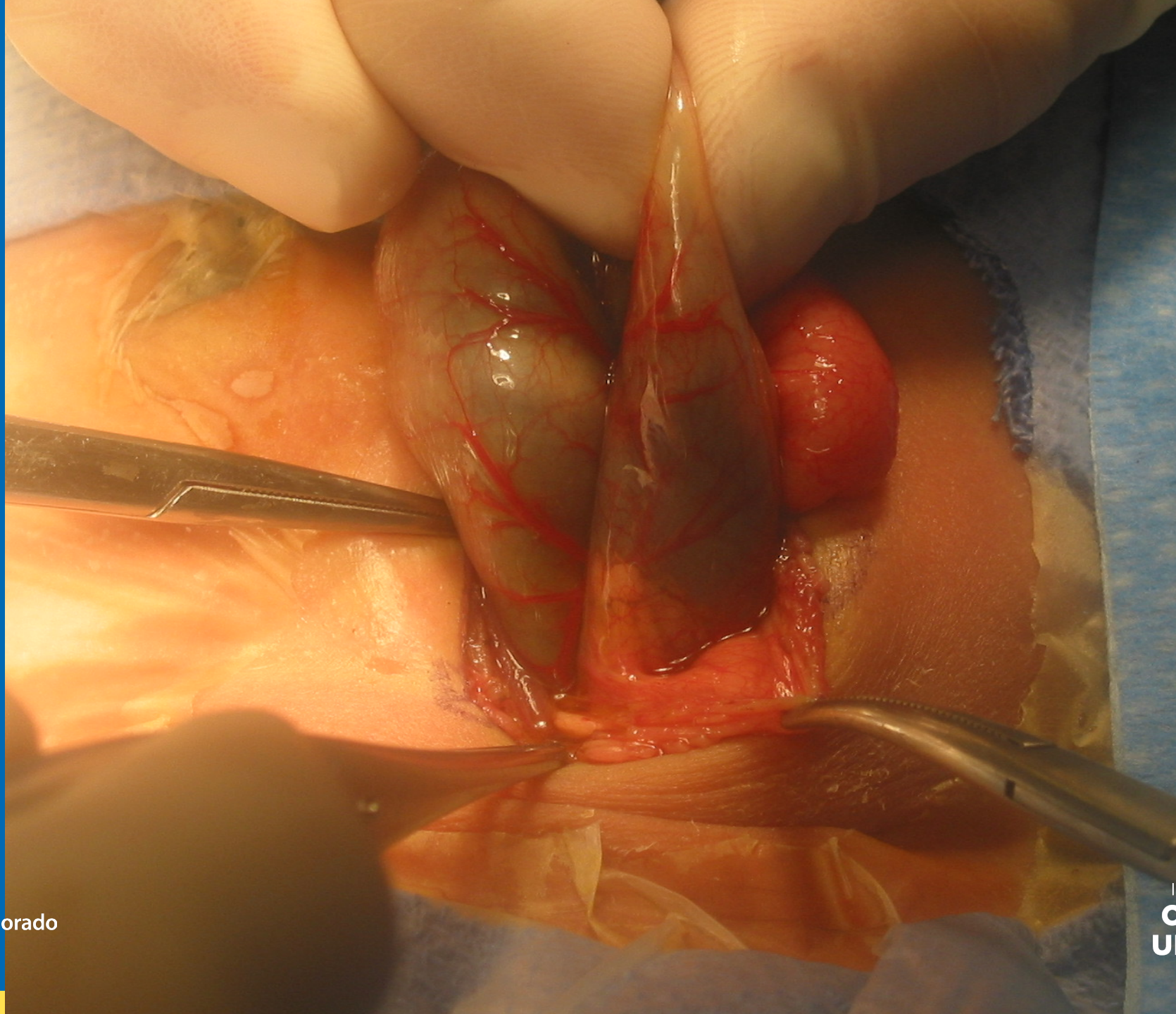
**Children's Hospital Colorado**  
*Here, it's different.™*

INTERNATIONAL CENTER FOR  
**COLORECTAL AND  
UROGENITAL CARE**



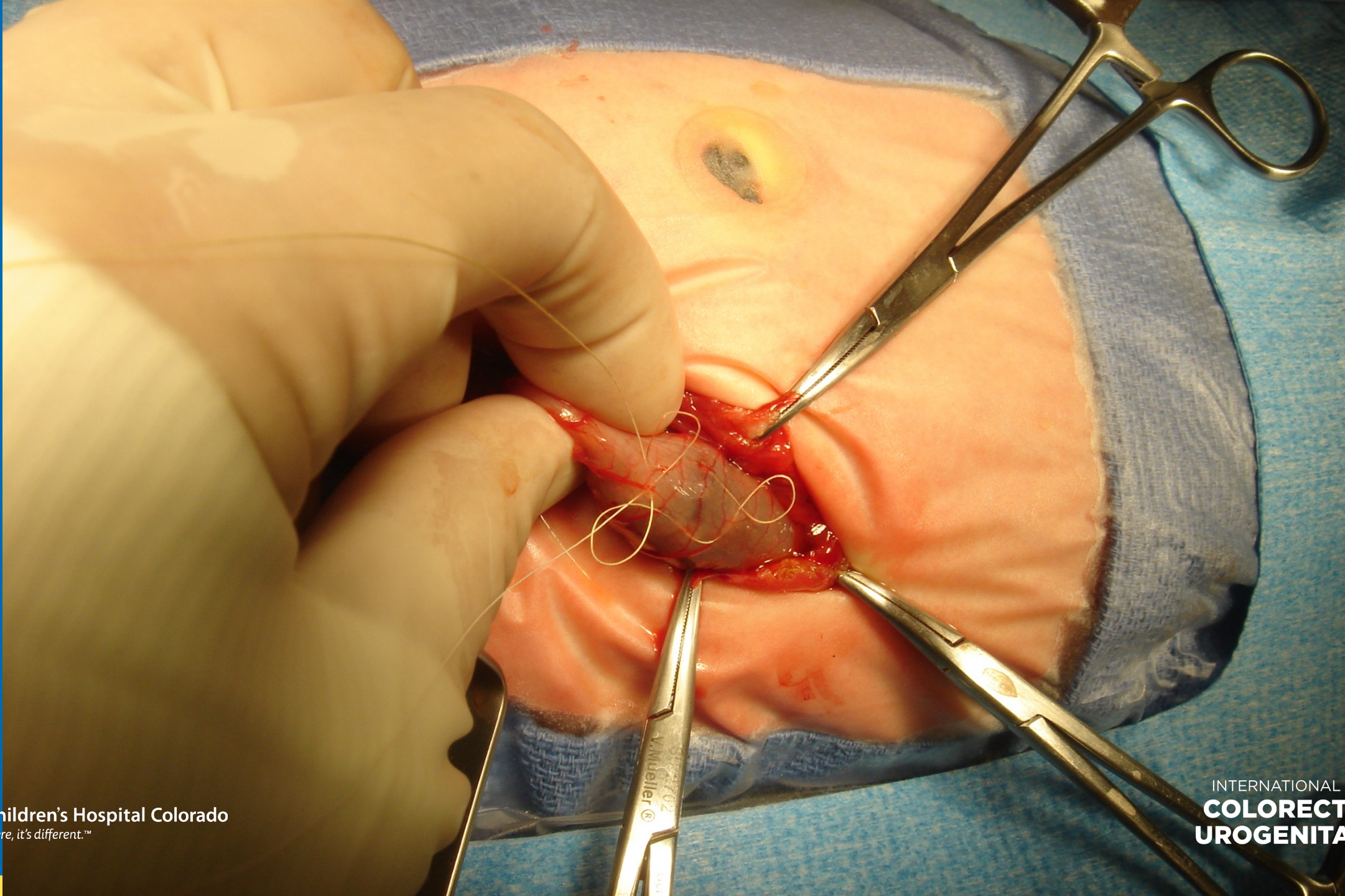
**Children's Hospital Colorado**  
*Here, it's different.™*

INTERNATIONAL CENTER FOR  
**COLORECTAL AND  
UROGENITAL CARE**



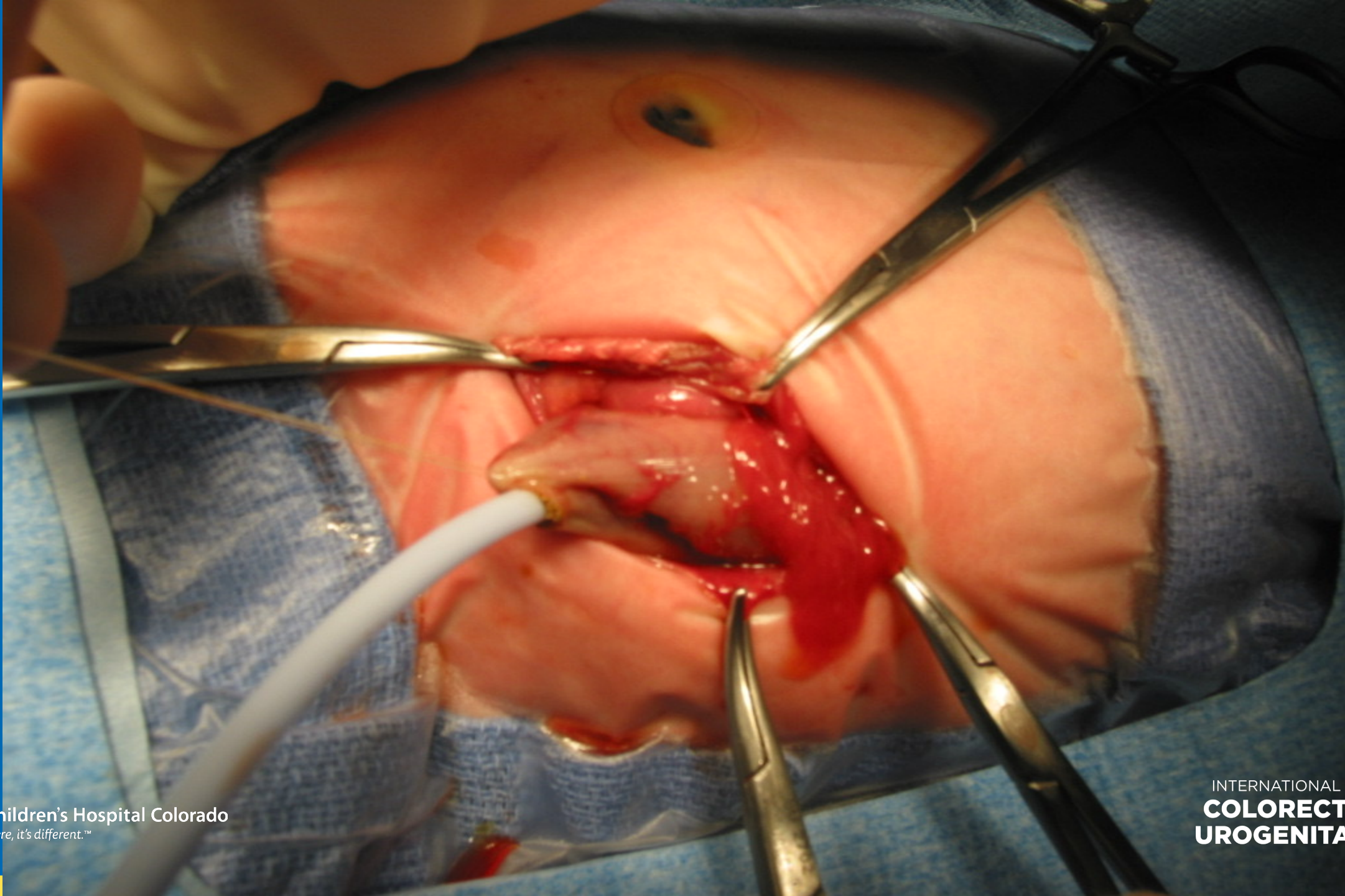
**Children's Hospital Colorado**  
*Here, it's different.™*

INTERNATIONAL CENTER FOR  
**COLORECTAL AND  
UROGENITAL CARE**



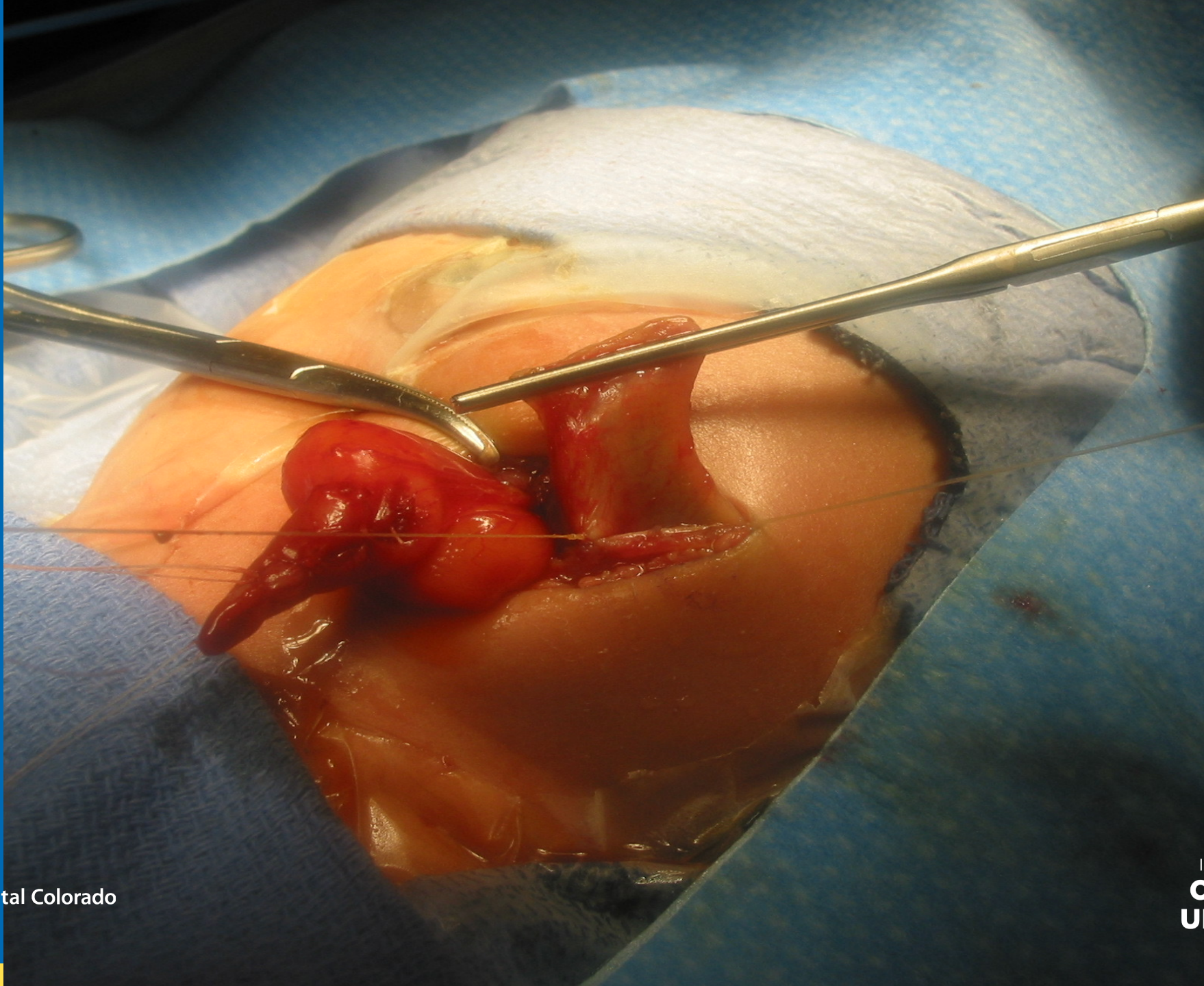
Children's Hospital Colorado  
Here, it's different.™

INTERNATIONAL CENTER FOR  
**COLORECTAL AND  
UROGENITAL CARE**



Children's Hospital Colorado  
*Here, it's different.™*

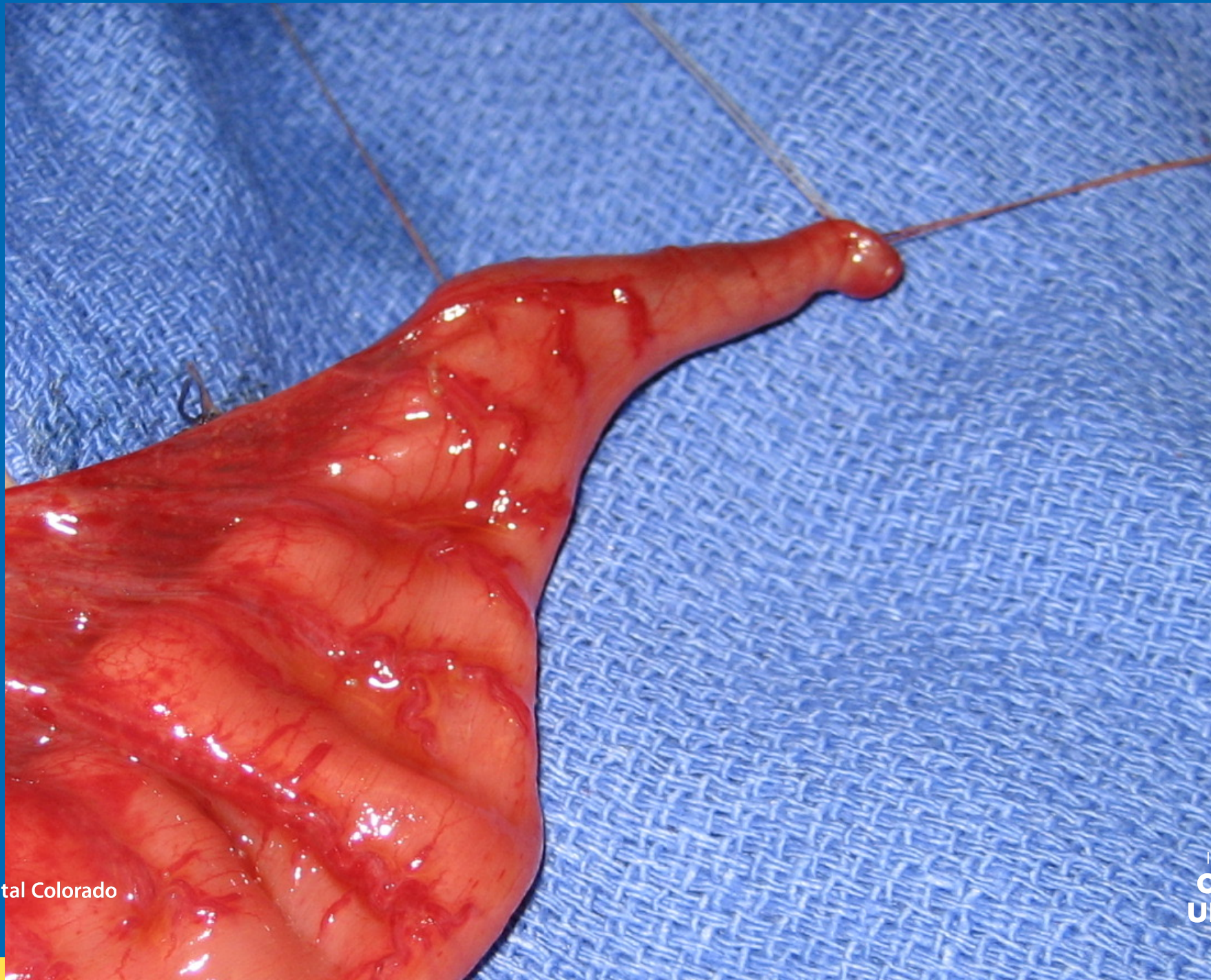INTERNATIONAL CENTER FOR  
**COLORECTAL AND  
UROGENITAL CARE**



**Children's Hospital Colorado**  
*Here, it's different.™*

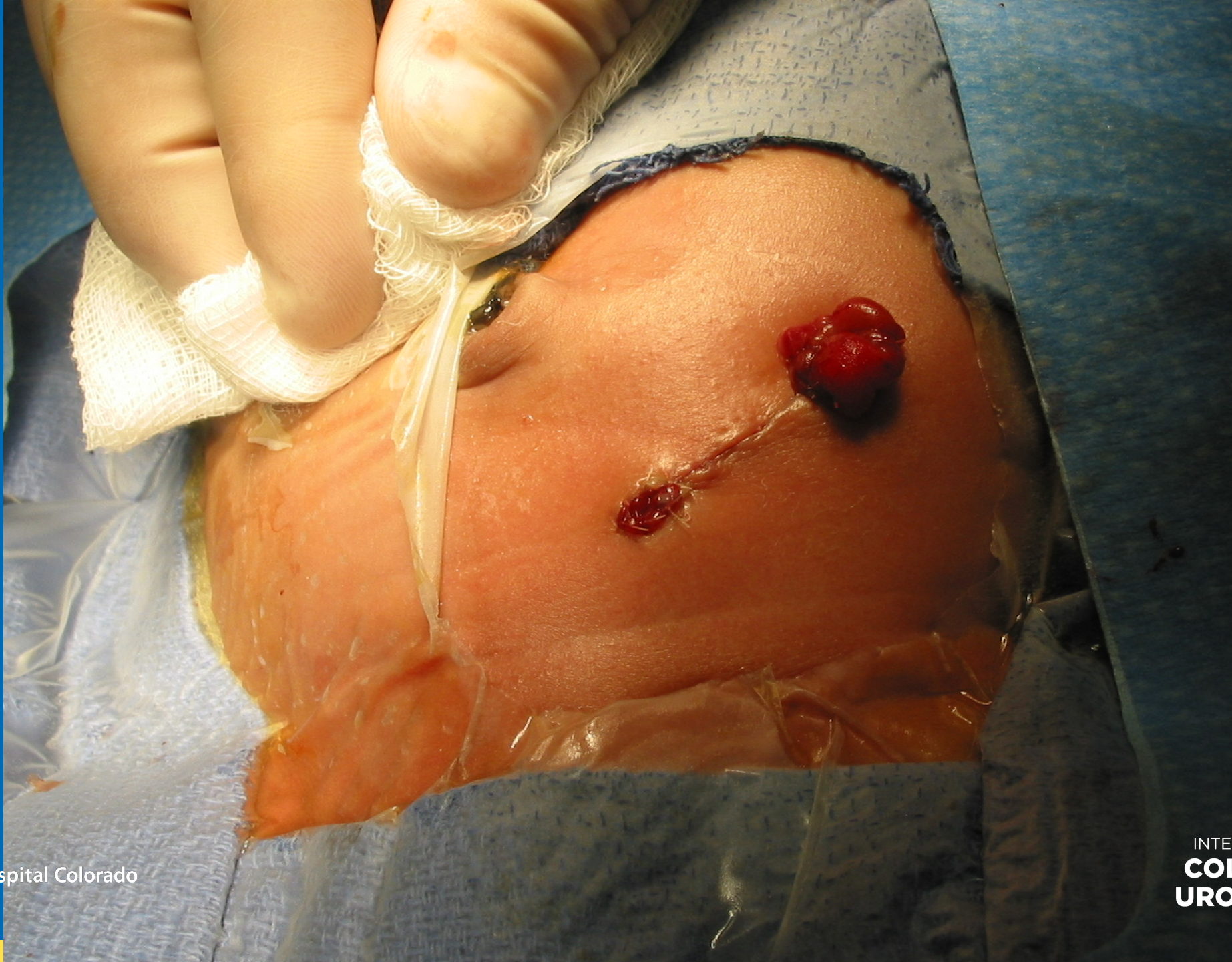INTERNATIONAL CENTER FOR  
**COLORECTAL AND  
UROGENITAL CARE**





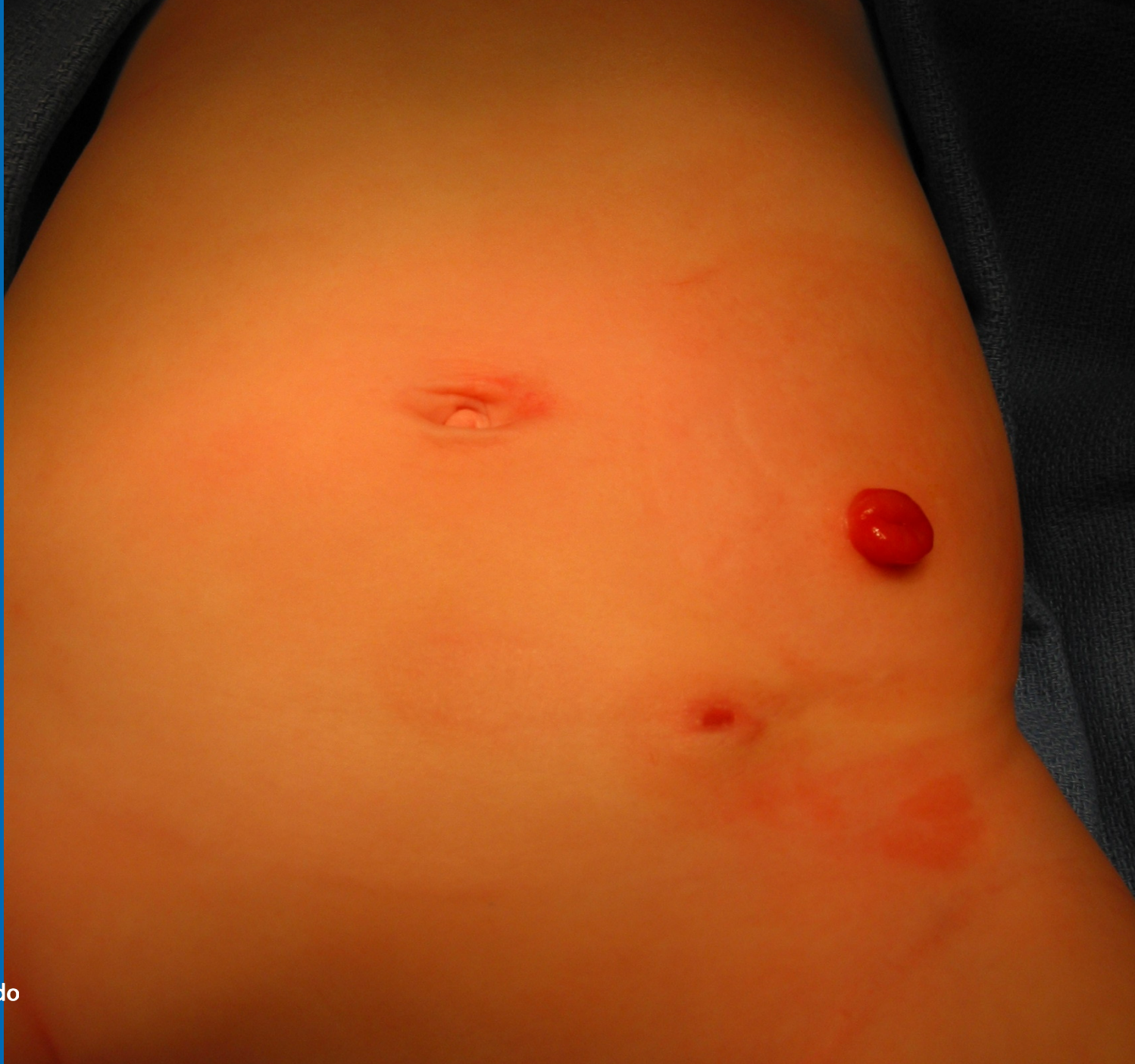**Children's Hospital Colorado**  
*Here, it's different.™*

INTERNATIONAL CENTER FOR  
**COLORECTAL AND  
UROGENITAL CARE**



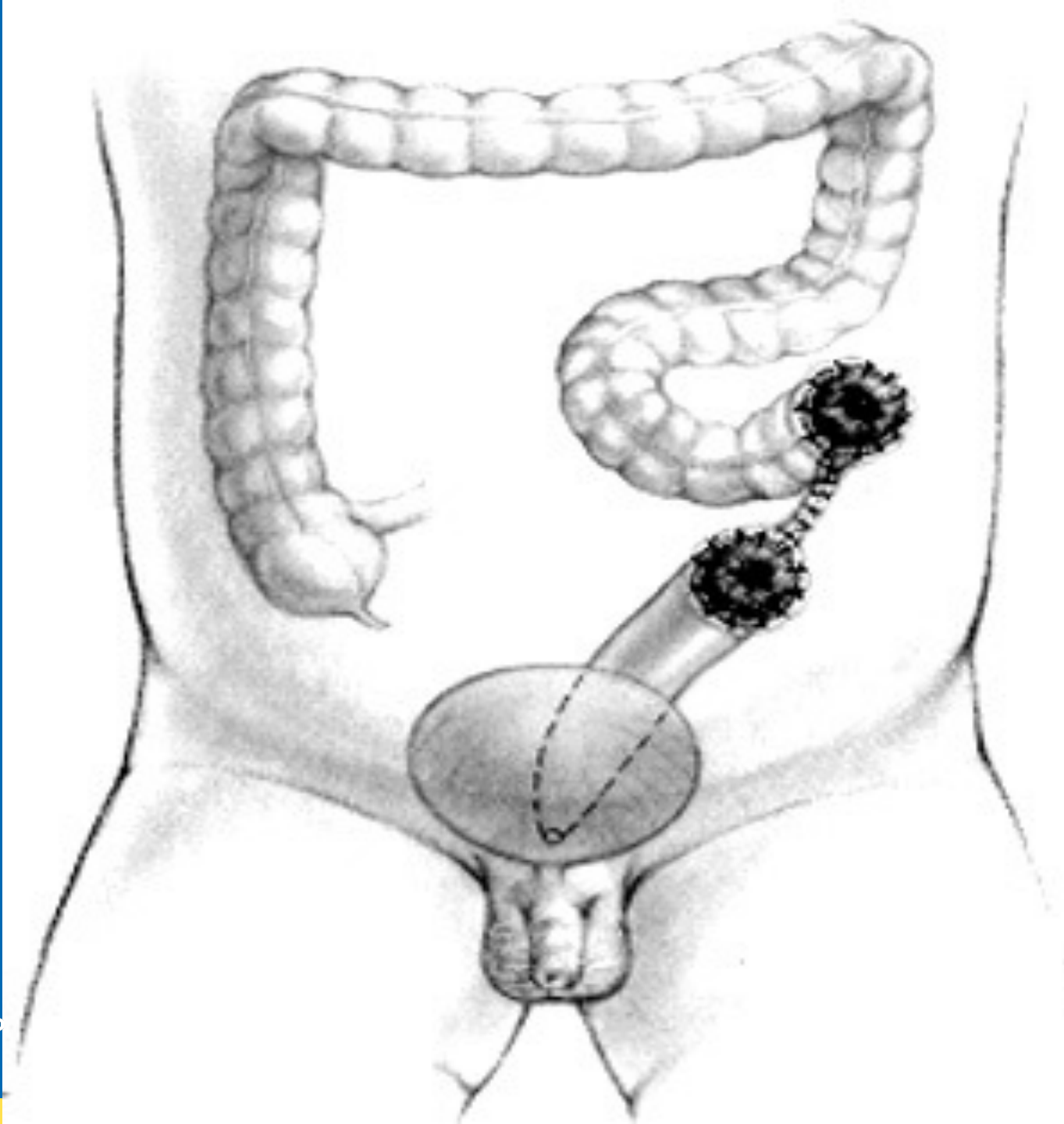
Children's Hospital Colorado  
*Here, it's different.™*

INTERNATIONAL CENTER FOR  
**COLORECTAL AND  
UROGENITAL CARE**



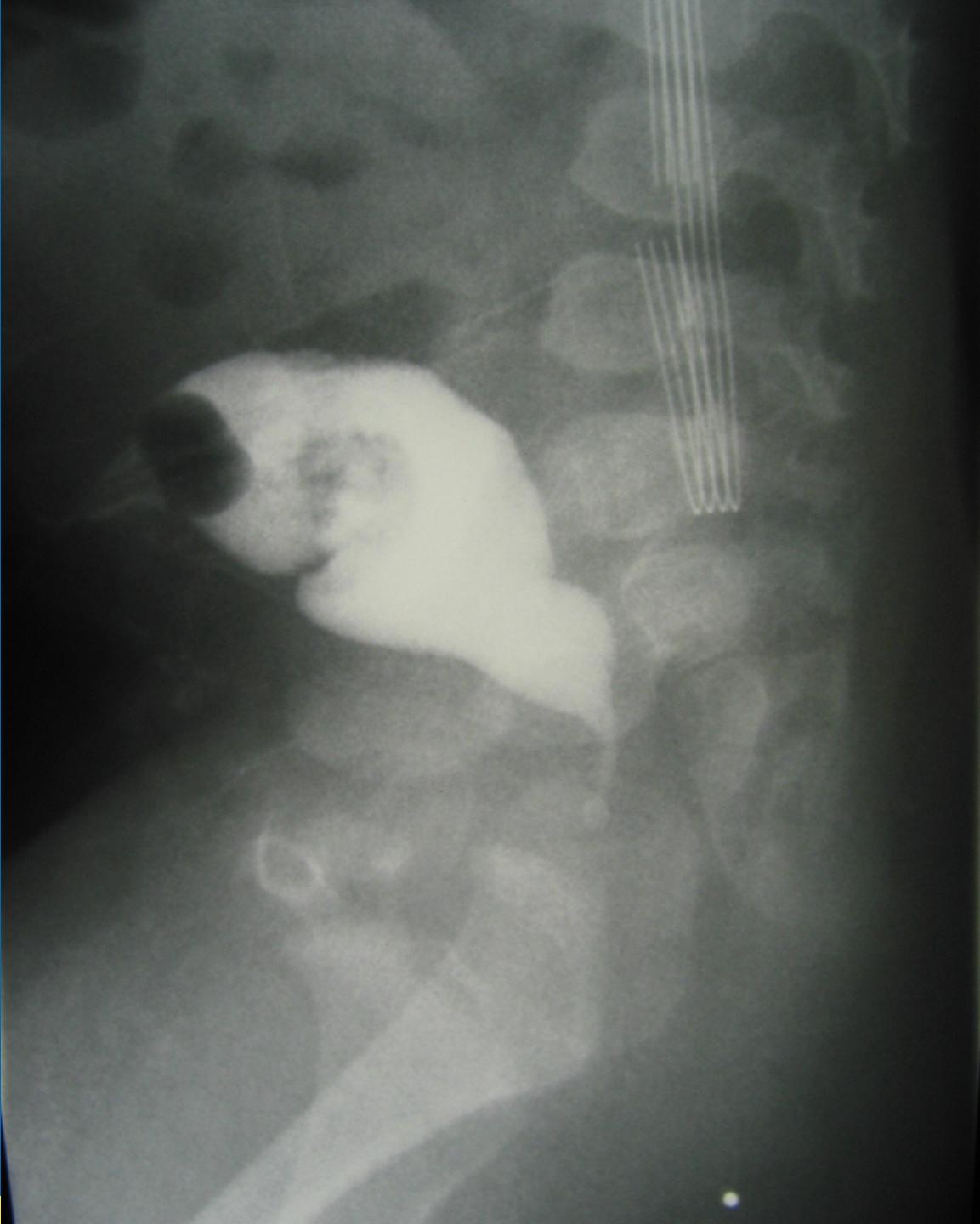**Children's Hospital Colorado**  
*Here, it's different.™*

INTERNATIONAL CENTER FOR  
**COLORECTAL AND  
UROGENITAL CARE**



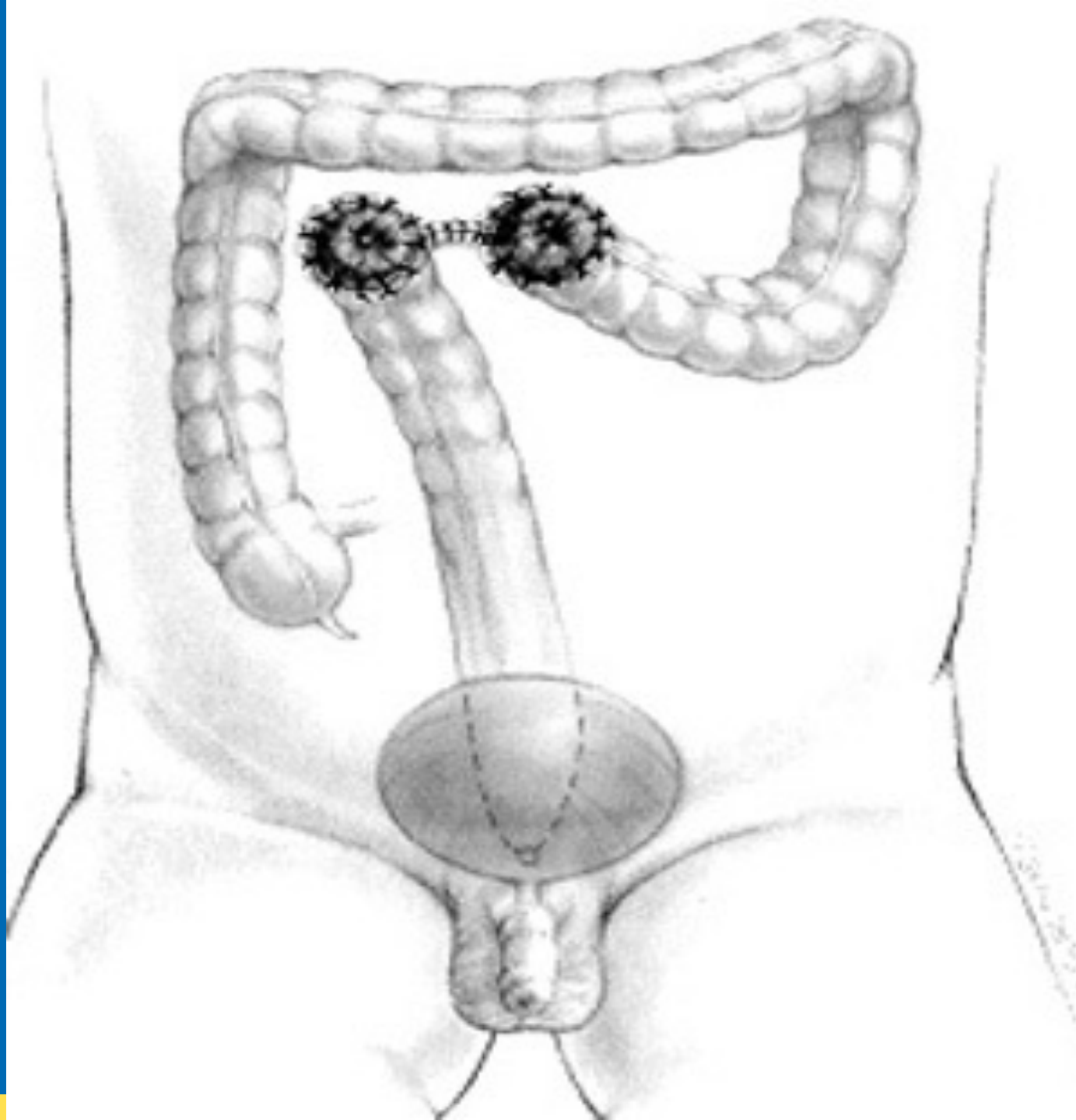
Children's Hospital Colorado  
*Here, it's different.™*

INTERNATIONAL CENTER FOR  
**COLORECTAL AND  
UROGENITAL CARE**



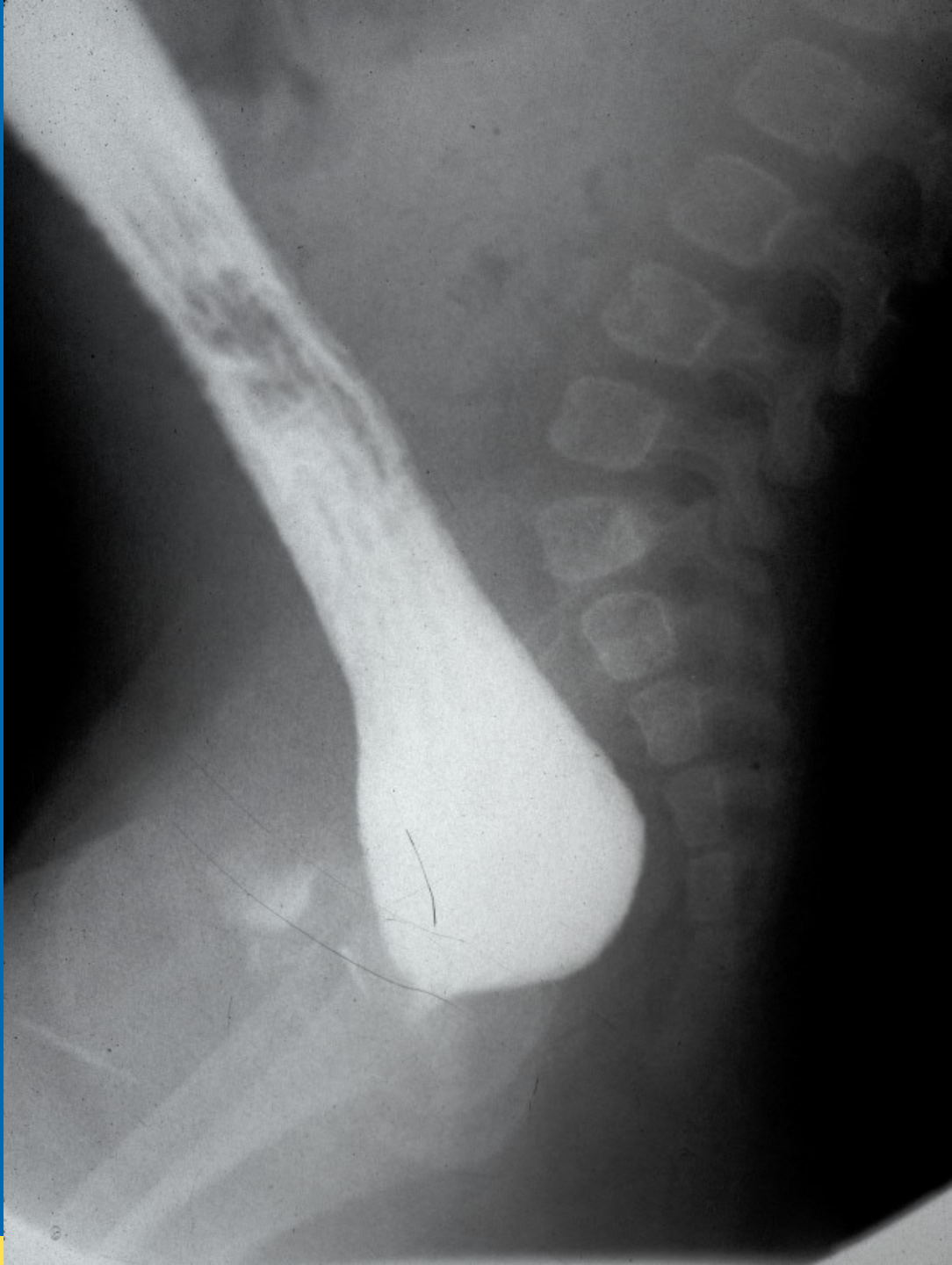**Children's Hospital Colorado**  
*Here, it's different.™*

INTERNATIONAL CENTER FOR  
**COLORECTAL AND  
UROGENITAL CARE**



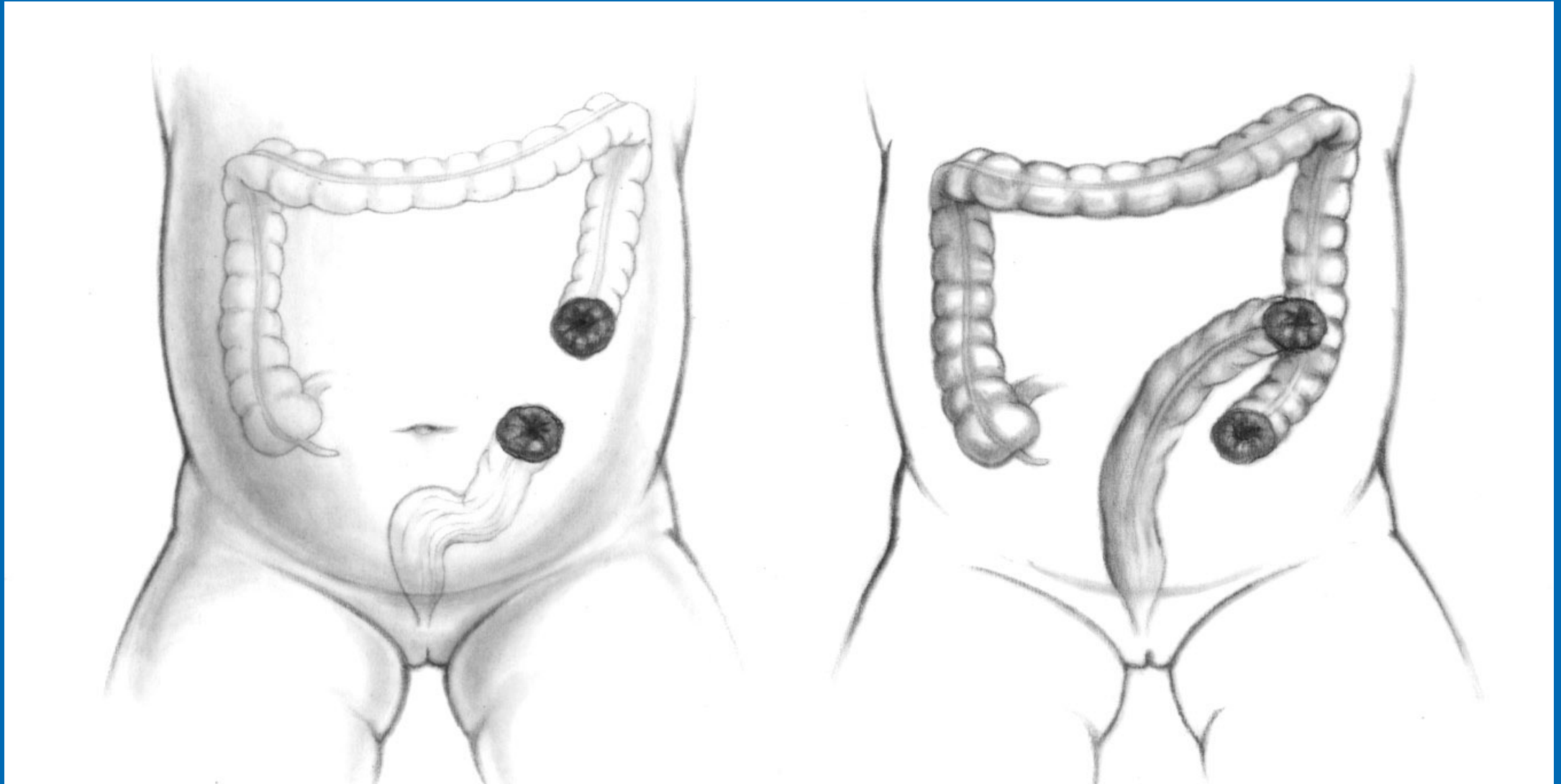
**Children's Hospital Colorado**  
*Here, it's different.™*

INTERNATIONAL CENTER FOR  
**COLORECTAL AND  
UROGENITAL CARE**



**Children's Hospital Colorado**  
*Here, it's different.™*

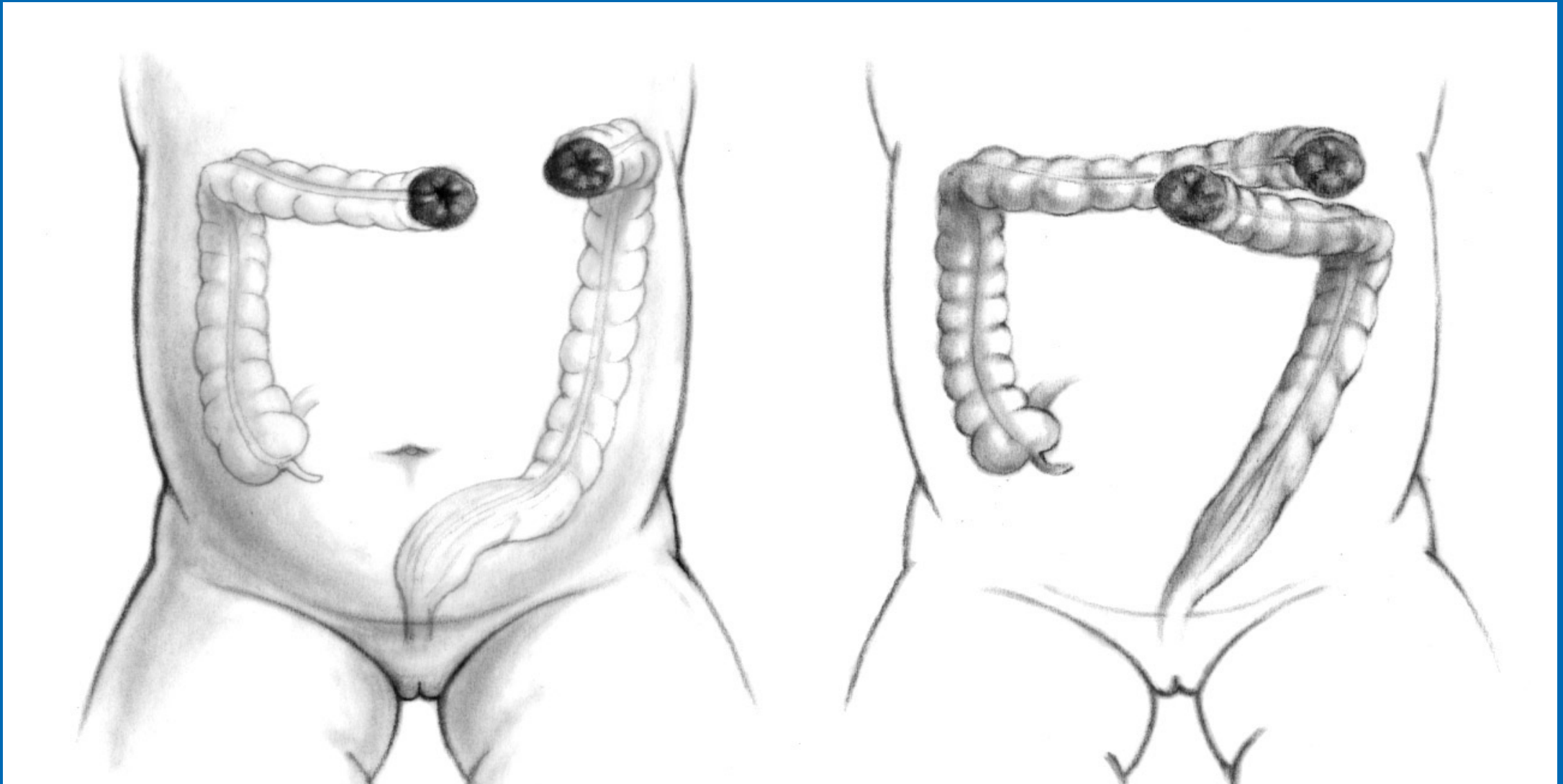
INTERNATIONAL CENTER FOR  
**COLORECTAL AND  
UROGENITAL CARE**



Children's Hospital Colorado  
Here, it's different.™

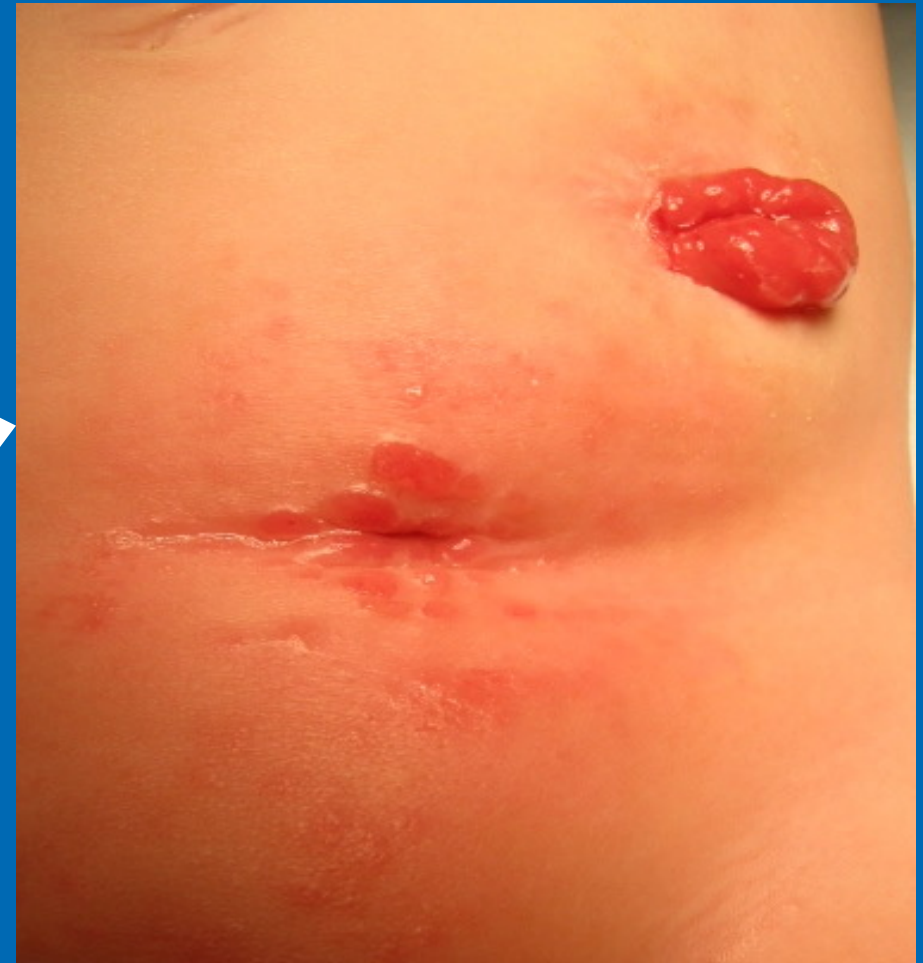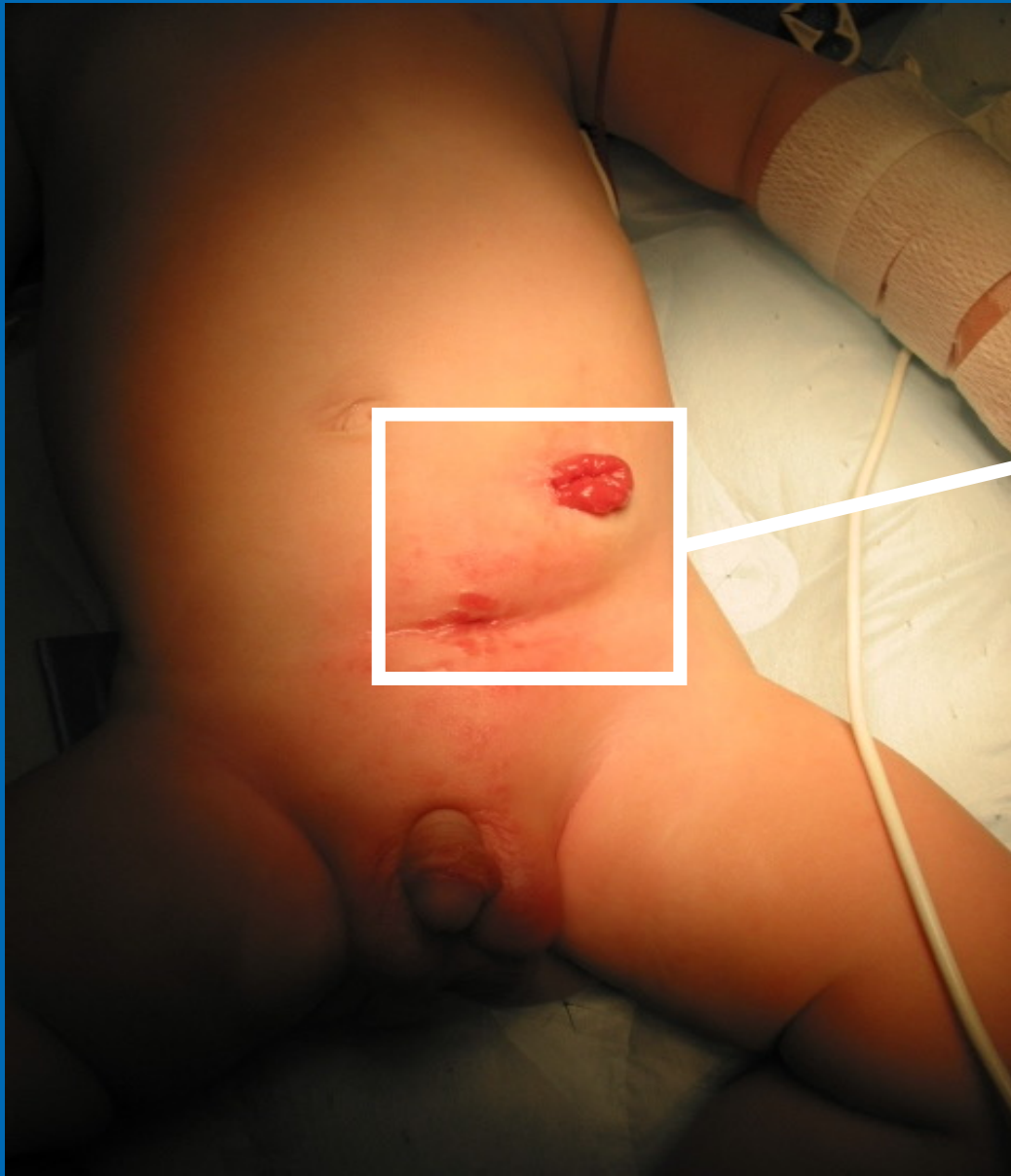
INTERNATIONAL CENTER FOR  
**COLORECTAL AND  
UROGENITAL CARE**





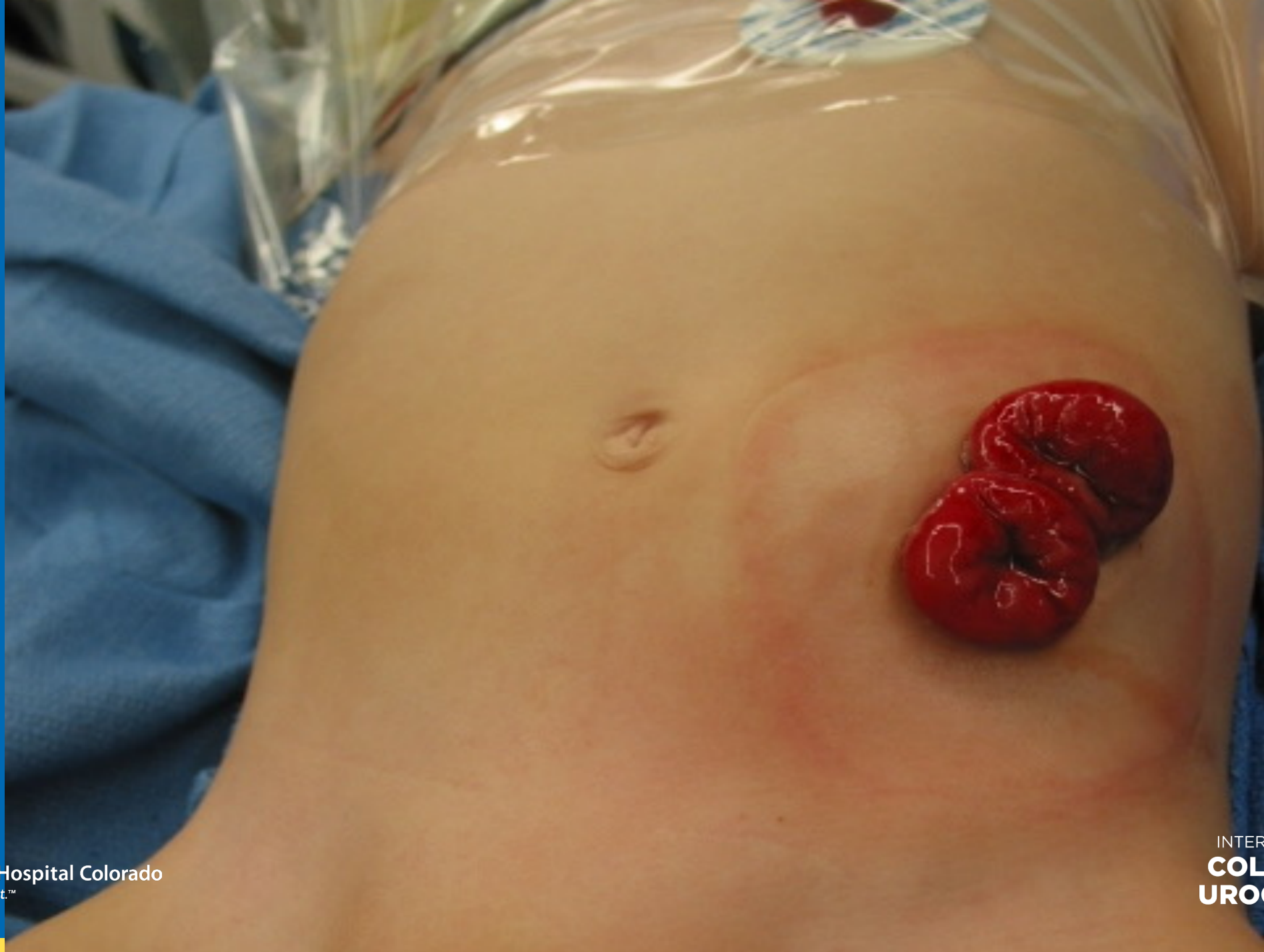Children's Hospital Colorado  
*Here, it's different.™*

INTERNATIONAL CENTER FOR  
**COLORECTAL AND  
UROGENITAL CARE**



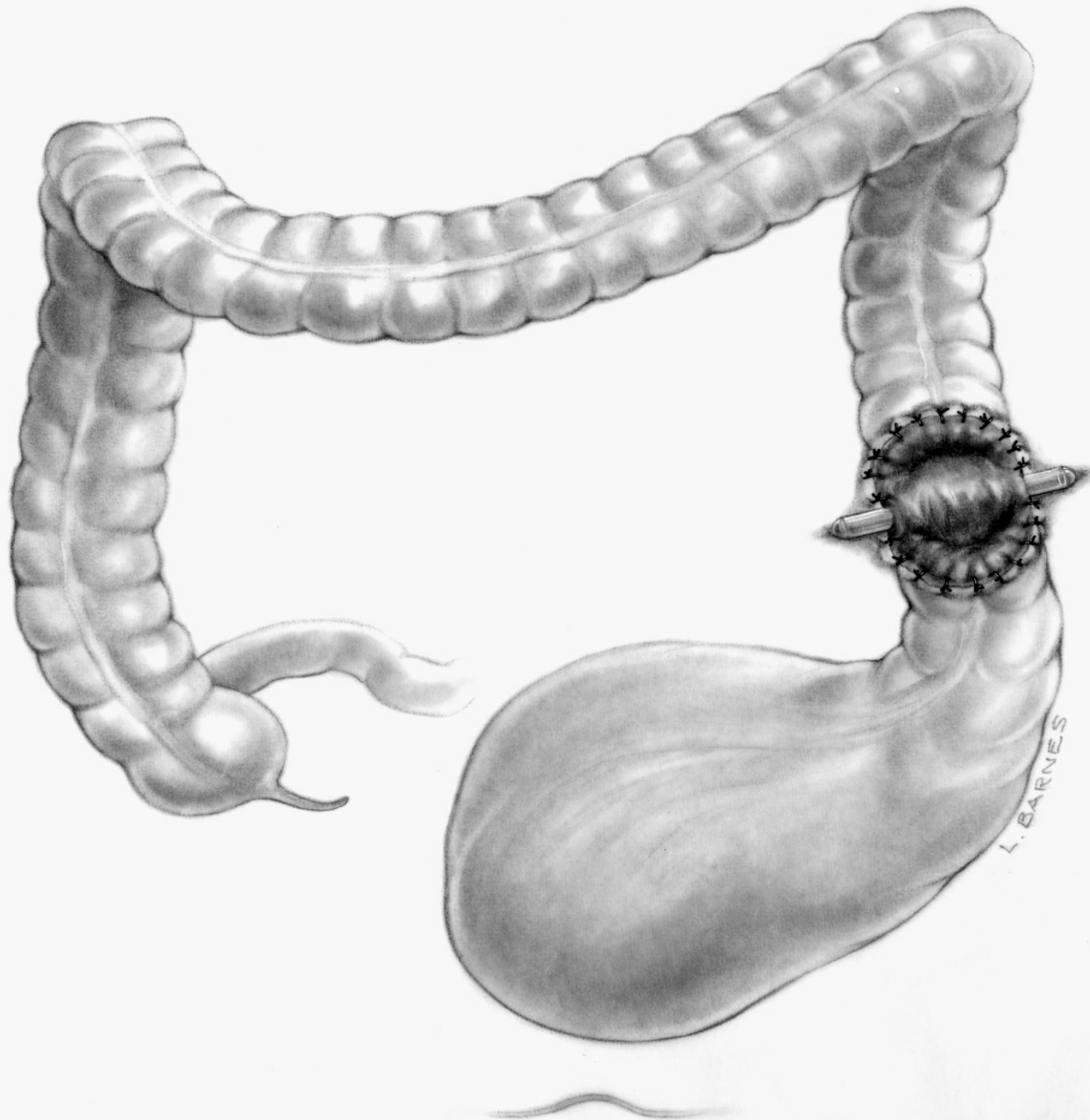
**Inverted**





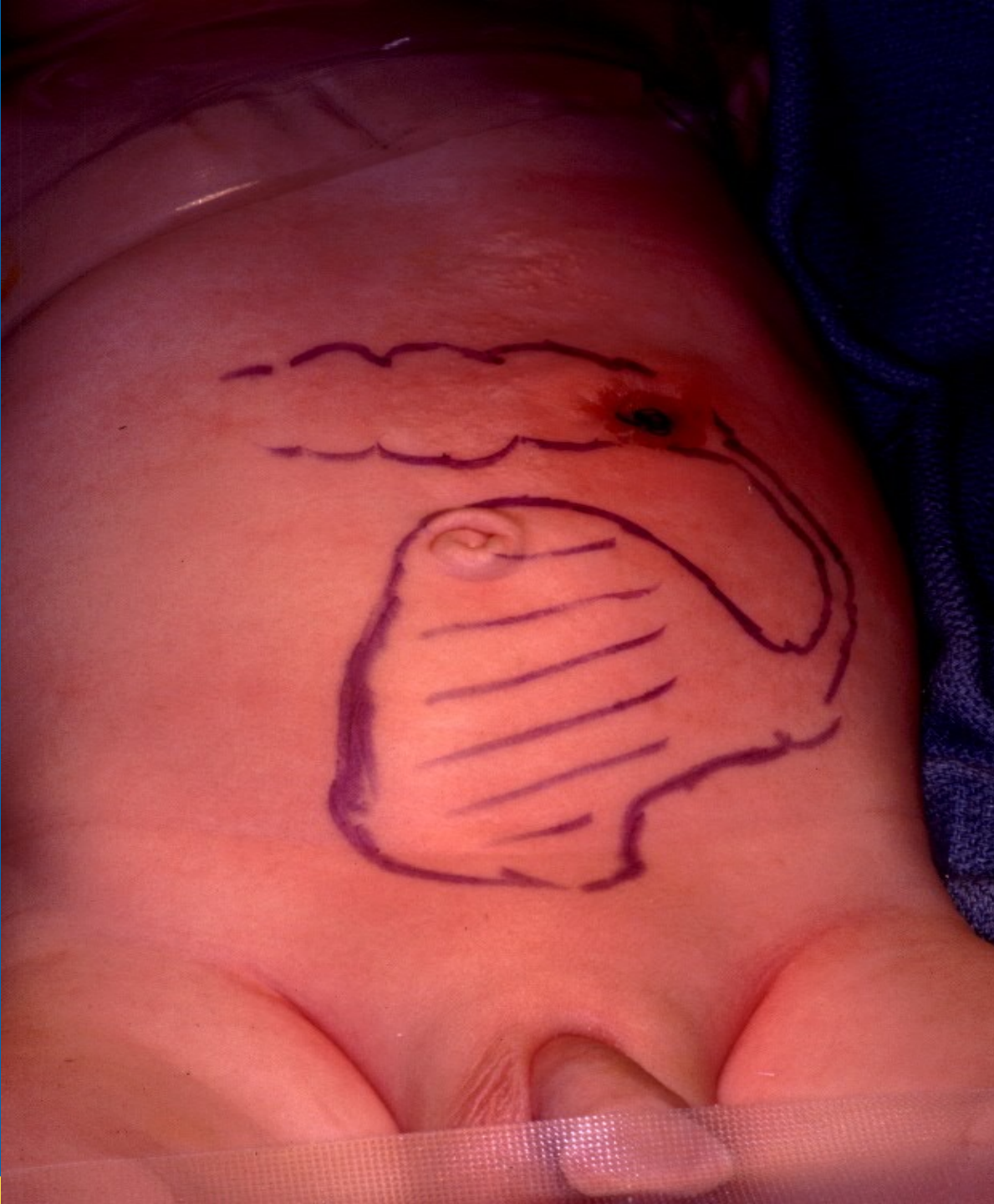**Children's Hospital Colorado**  
*Here, it's different.™*

INTERNATIONAL CENTER FOR  
**COLORECTAL AND  
UROGENITAL CARE**



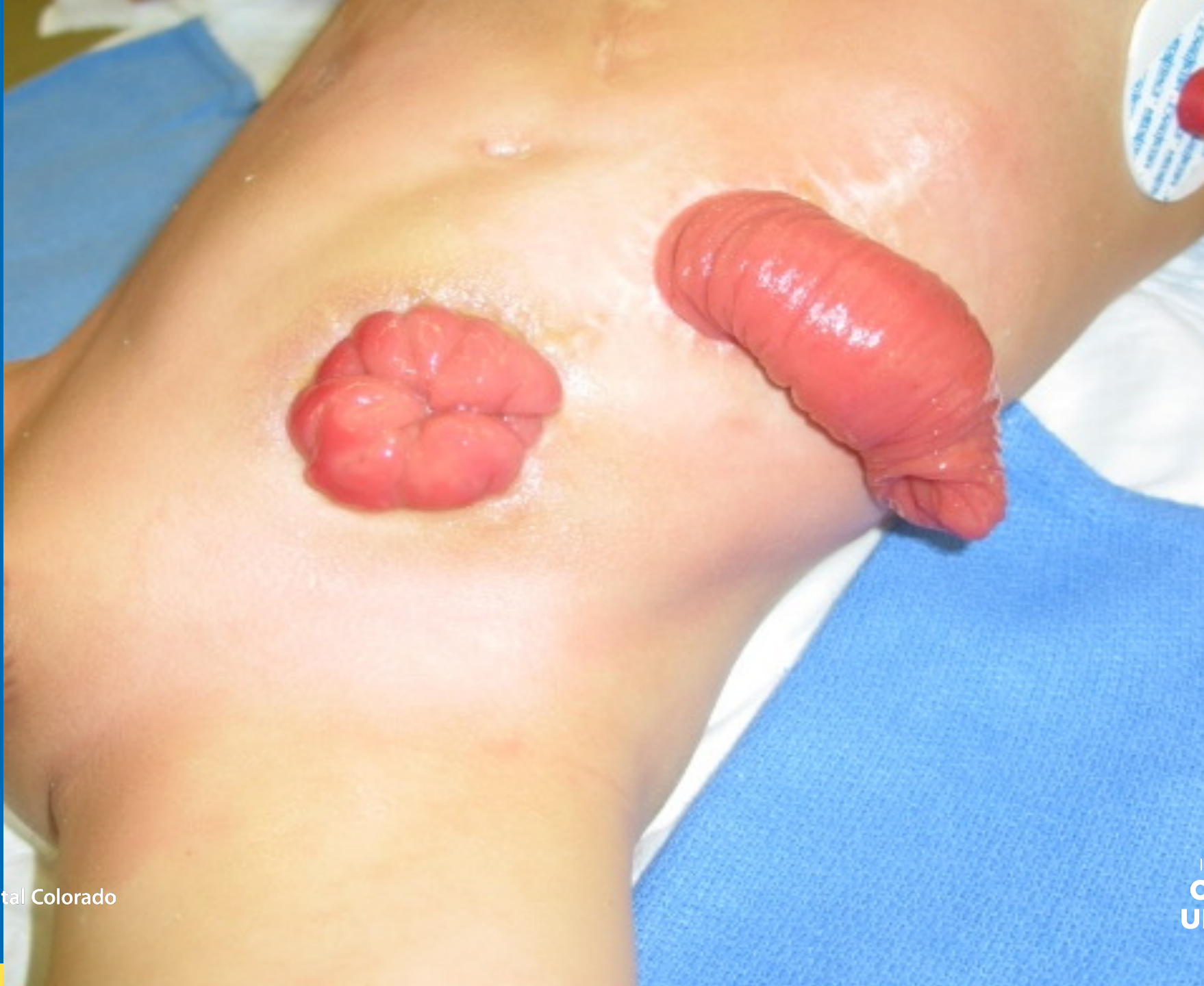Children's Hospital Colorado  
Here, it's different.™

INTERNATIONAL CENTER FOR  
**COLORECTAL AND  
UROGENITAL CARE**



**Children's Hospital Colorado**  
*Here, it's different.™*

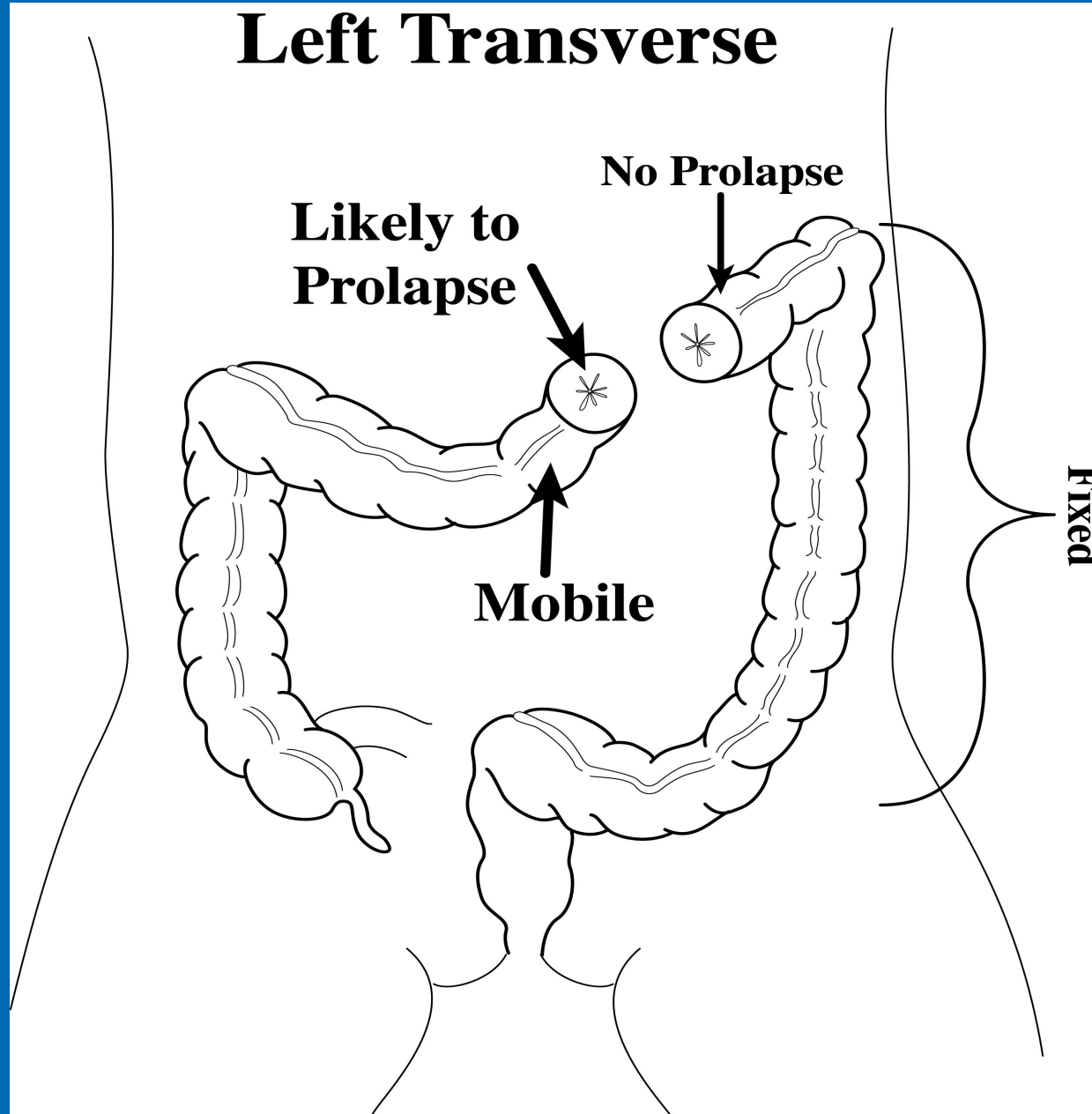
INTERNATIONAL CENTER FOR  
**COLORECTAL AND  
UROGENITAL CARE**



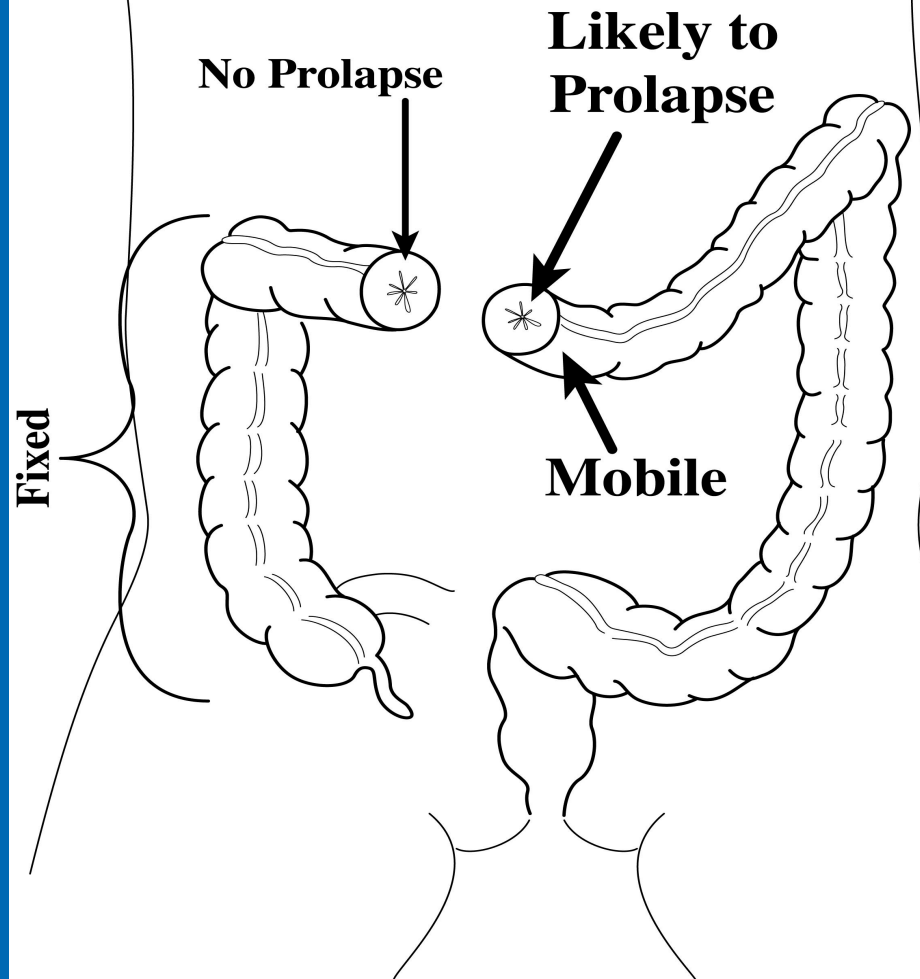
**Children's Hospital Colorado**  
*Here, it's different.™*

INTERNATIONAL CENTER FOR  
**COLORECTAL AND  
UROGENITAL CARE**

# Left Transverse

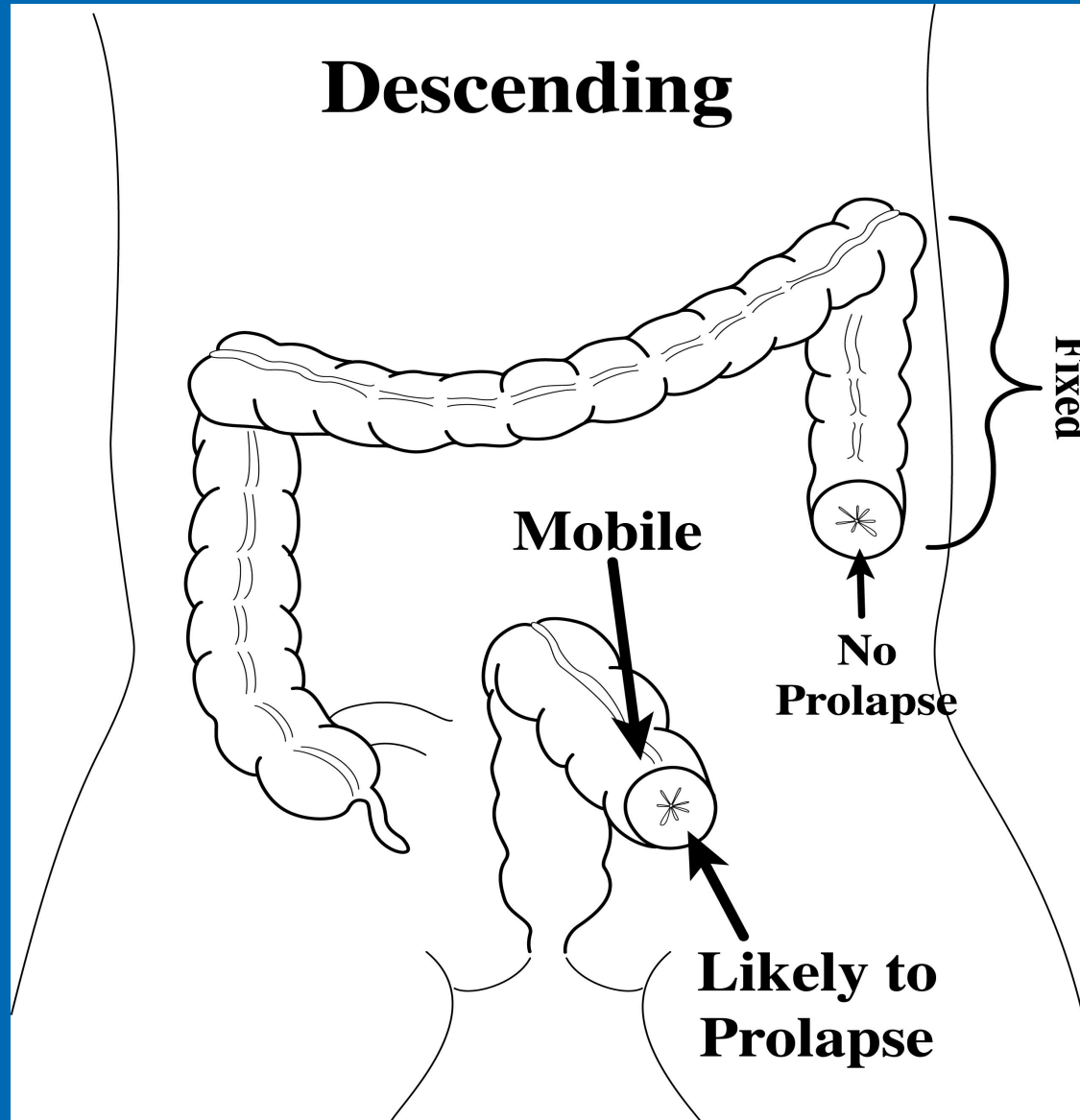


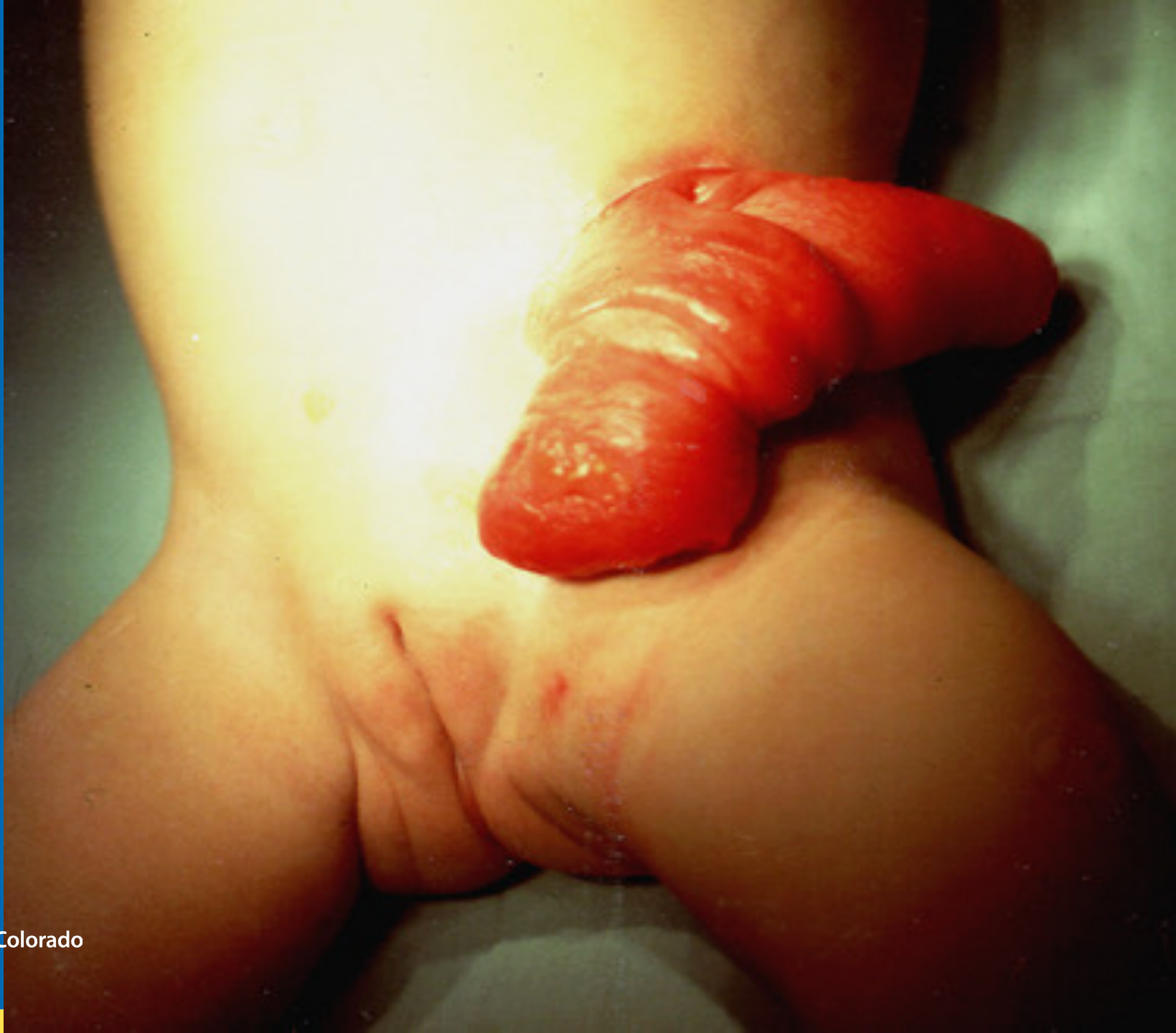# Right Transverse





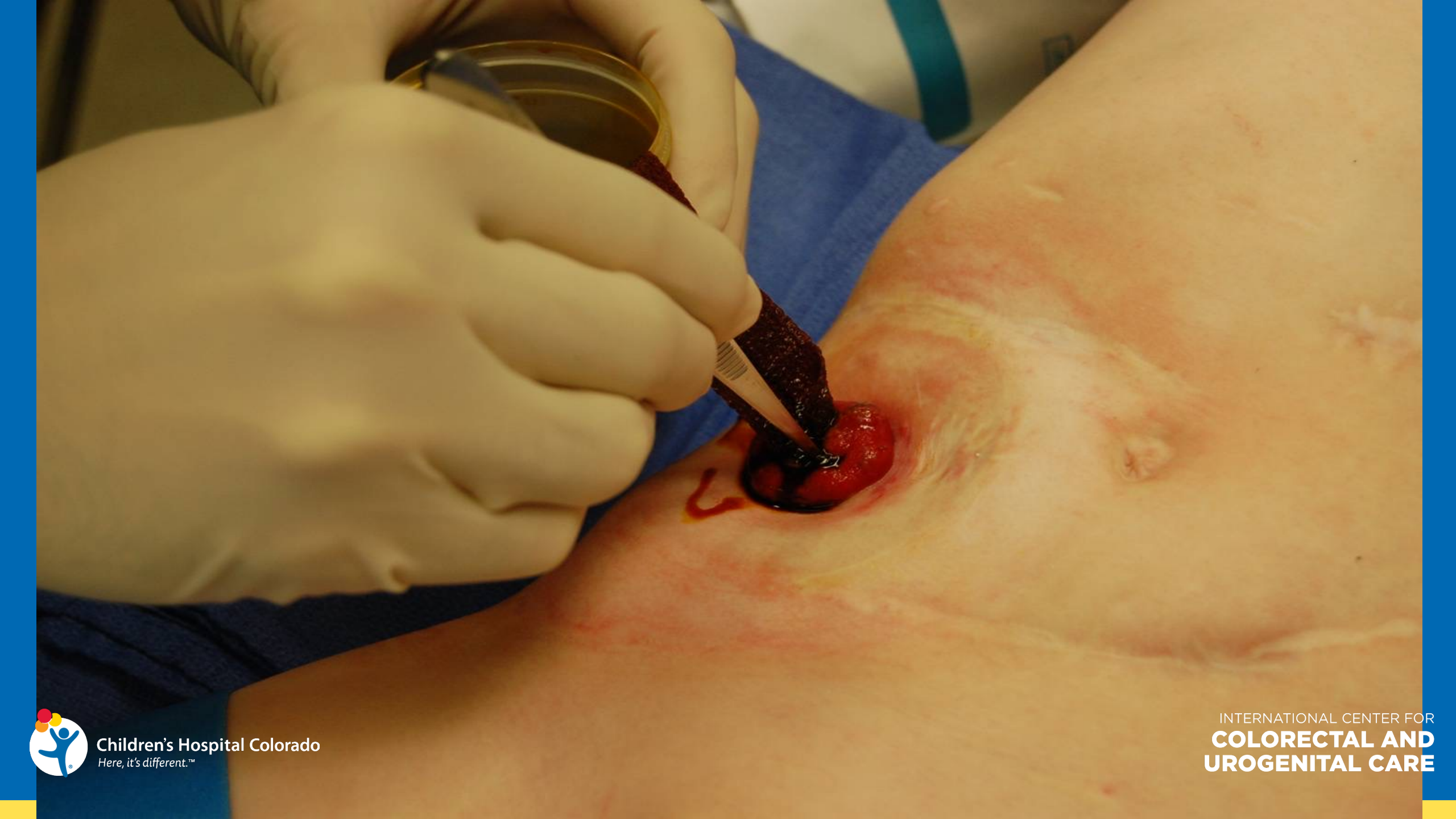# Descending





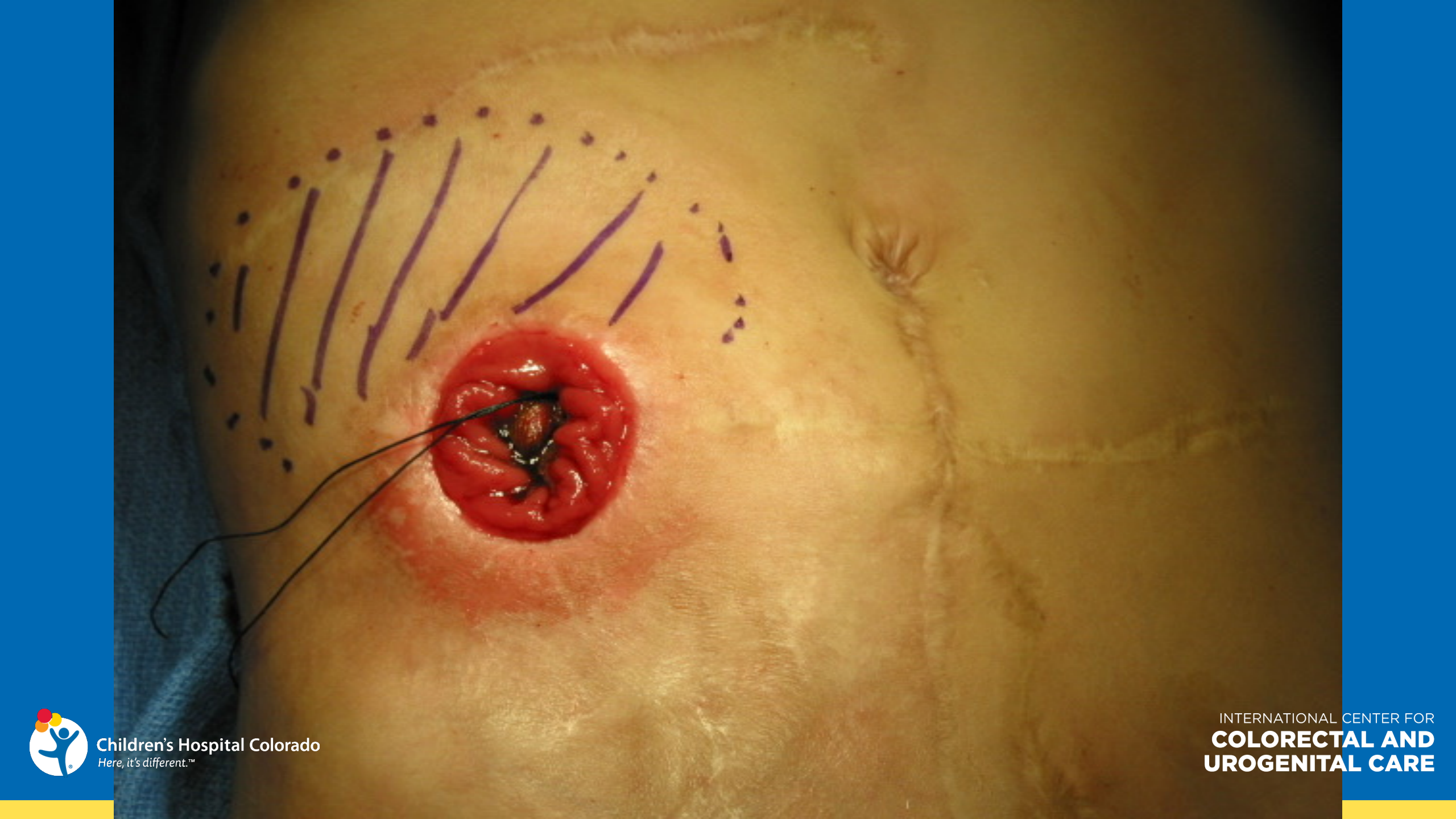
**Children's Hospital Colorado**  
*Here, it's different.™*

INTERNATIONAL CENTER FOR  
**COLORECTAL AND  
UROGENITAL CARE**



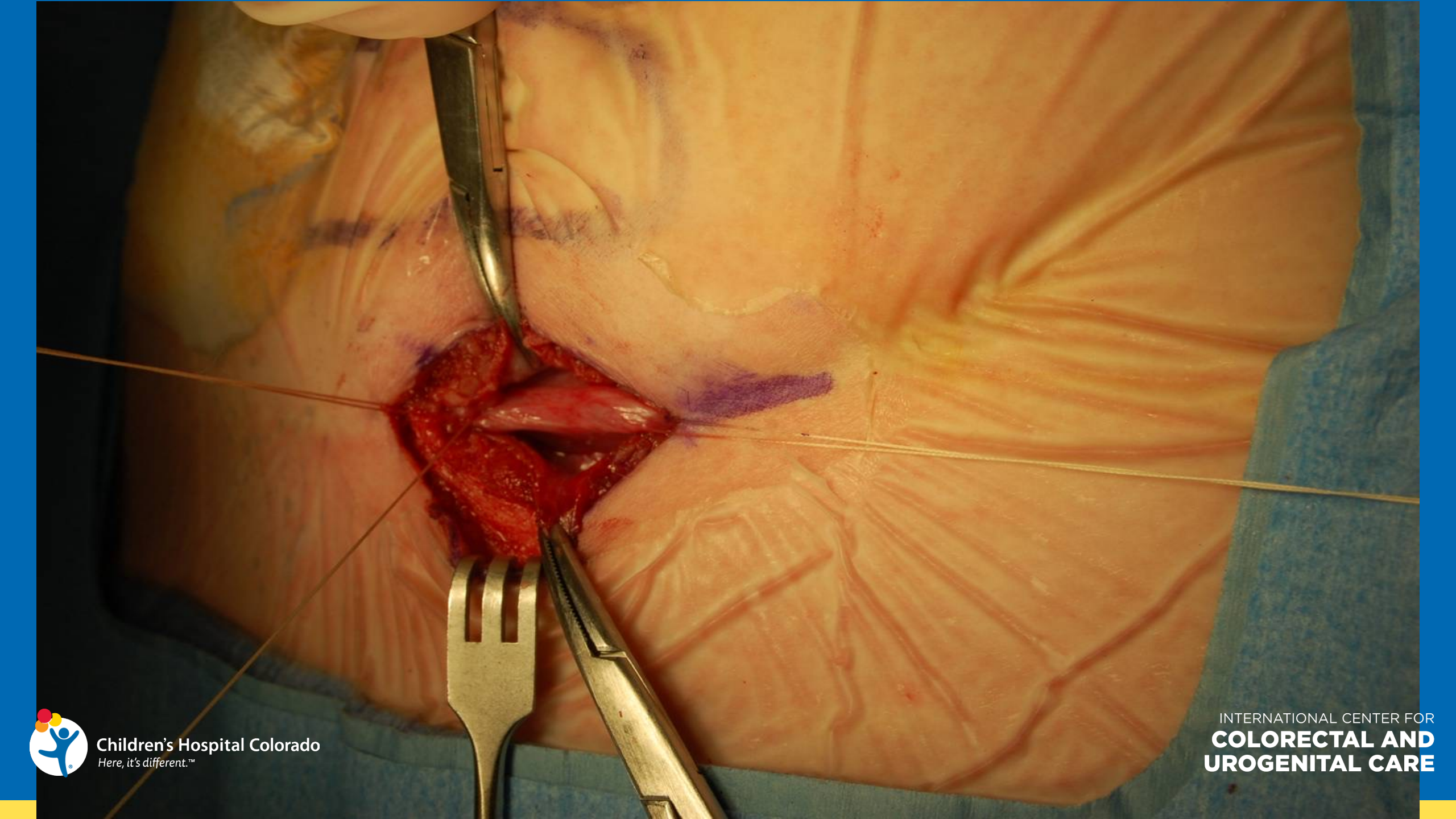
**Children's Hospital Colorado**  
*Here, it's different.™*

INTERNATIONAL CENTER FOR  
**COLORECTAL AND  
UROGENITAL CARE**



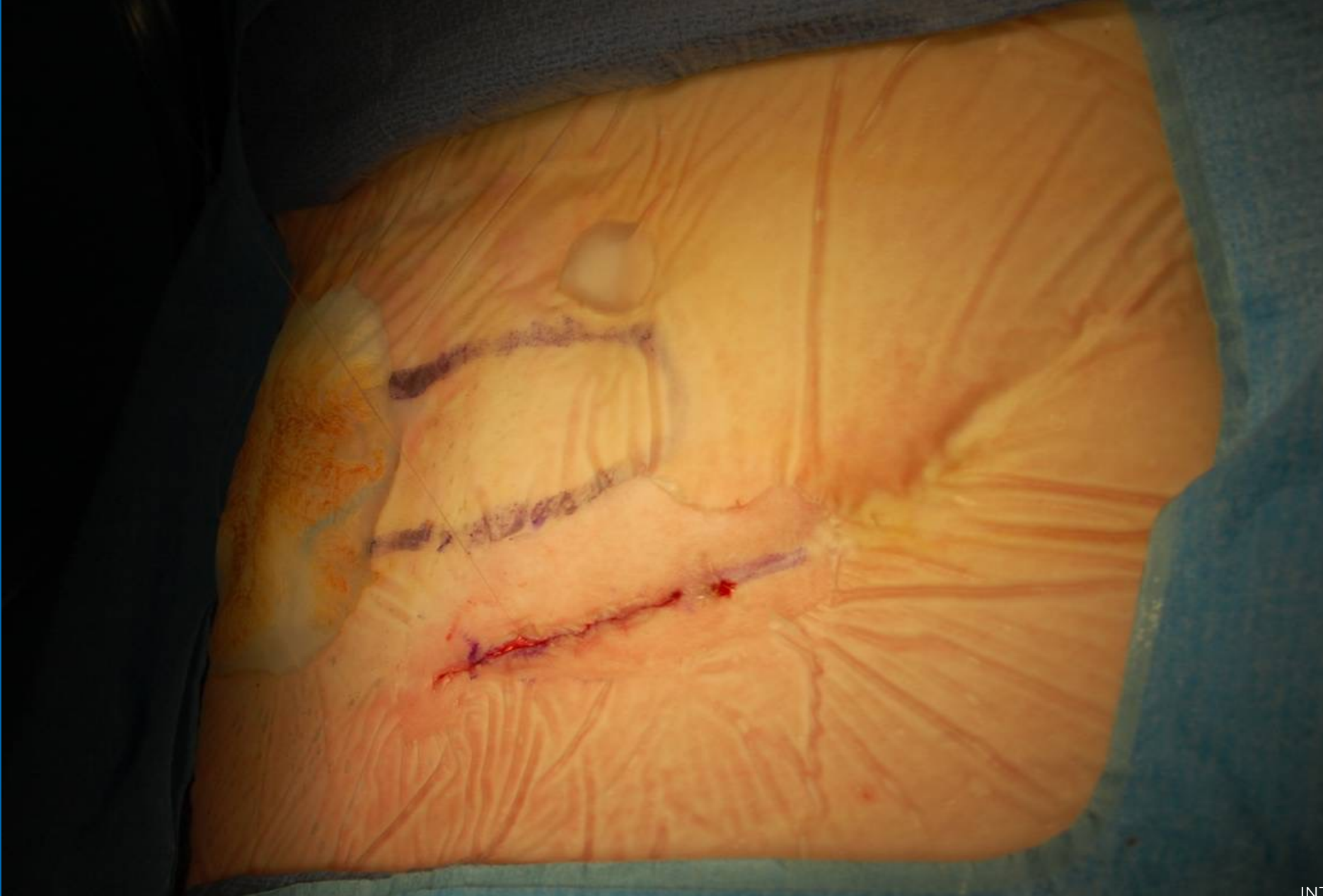**Children's Hospital Colorado**  
*Here, it's different.™*

INTERNATIONAL CENTER FOR  
**COLORECTAL AND  
UROGENITAL CARE**



**Children's Hospital Colorado**  
*Here, it's different.™*

INTERNATIONAL CENTER FOR  
**COLORECTAL AND  
UROGENITAL CARE**



**Children's Hospital Colorado**  
*Here, it's different.™*

INTERNATIONAL CENTER FOR  
**COLORECTAL AND  
UROGENITAL CARE**

[alberto.pena@cuanschutz.edu](mailto:alberto.pena@cuanschutz.edu)

[andrea.bischoff@cuanschutz.edu](mailto:andrea.bischoff@cuanschutz.edu)

[luis.delatorre@cuanschutz.edu](mailto:luis.delatorre@cuanschutz.edu)



Children's Hospital Colorado  
*Here, it's different.™*

INTERNATIONAL CENTER FOR  
**COLORECTAL AND  
UROGENITAL CARE**



**Children's Hospital Colorado**  
*Here, it's different.™*

INTERNATIONAL CENTER FOR  
**COLORECTAL AND  
UROGENITAL CARE**





**Children's Hospital Colorado**  
*Here, it's different.™*